

Myeloid sarcoma on the scalp of a patient with acute myeloid leukemia^{☆,☆☆}

Dear Editor,

A 57-year-old female patient, Caucasian, with a previous diagnosis of hypertension, using losartan, and with acute myeloid leukemia for one year. She underwent chemotherapy with daunorubicin for three months and was in maintenance with transretinic acid 70 mg at the time of the consultation. She sought the dermatology service because of painful and itchy lesions on the scalp, which had arisen 20 days before and were preceded by local burning (Fig. 1). The proposed diagnostic hypotheses were cutaneous metastasis, cutaneous T-cell lymphoma, and pharmacodermia. An anatomopathological examination was performed, which demonstrated a dense diffuse infiltration of lymphocytic cells, atypical and large cells, four-to-five times the usual size of mature lymphocytes, with bizarre formats and convoluted nuclei in the superficial, intermediate, and deep dermis, with extension to the hypodermis, sparing the epidermis (Fig. 2). Immunohistochemical study of the lesion revealed diffuse positivity for CD43 in 80% of cell infiltrate, diffuse positivity for myeloperoxidase in more than 90% of cells, Ki67 positivity in about 30% of cells, and granzyme, alk1, CD3, CD20, and CD30 negativity (Fig. 3). Therefore, the diagnosis of myeloid sarcoma was established. At the end of the chemotherapy, she presented total remission of the hematological alterations; however, as she maintained lesions on the scalp, retreatment with radiotherapy was utilized. However, the lesions remained unchanged and the patient evolved with relapse of myeloid leukemia, with a new chemotherapy protocol initiated by the hematology team.

Myeloid sarcoma, chloroma, or granulocytic sarcoma is defined by the World Health Organization as a solid tumor consisting of myeloblasts occurring in an anatomical site other than the bone marrow. Therefore, it should be remembered as a differential diagnosis of any atypical cellular infiltrate.¹ In addition, it is a rare tumor, with an incidence of two in every 1,000,000 inhabitants, and is difficult to diagnose. This disease has great association with myeloproliferative diseases, especially with acute myeloid leukemia, and may be the first manifestation of the disease in 5% of cases. Cutaneous manifestations are more often seen as hardened, purplish, purpuric-based nodules, about 1–2.5 cm in diameter and more rarely as plaques, erythematous macules, blisters, and ulcers; they may present as an erythematous rash in a polymorphic pattern. It more commonly presents as a solitary lesion in places like soft tissues, bones, peritoneum, and lymph nodes. In the case reported, the lesion was present on the scalp, a rare site of dis-

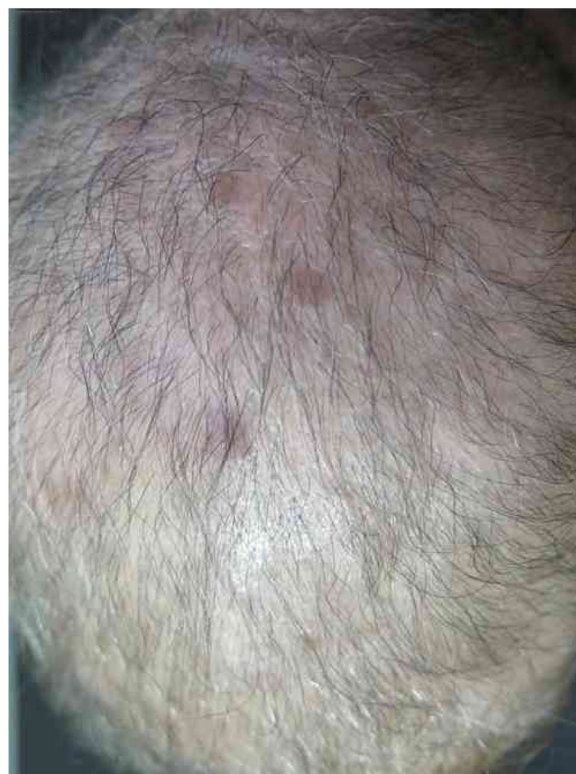

Figure 1 Scalp lesions.

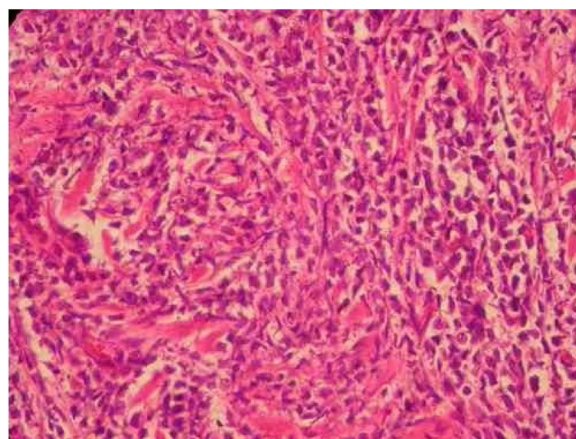


Figure 2 Intense diffuse lymphocytic infiltrate of atypical cells with extension to the hypodermis and sparing the epidermis. Cells are large in size, four-to-five times the usual size of mature lymphocytes, with bizarre formats and convoluted nuclei. $\times 40$ magnification. Coloration: Hematoxylin & eosin.

ease occurrence.² Studies have shown that the incidence of head and neck injuries is between 12% and 48%. The diagnosis is made through a biopsy with anatomopathological and immunohistochemical study, demonstrating infiltration by myeloblasts. The diagnosis by immunohistochemistry is mainly through positivity for the Leder stain, for lysozyme antigens, and for myeloperoxidase antigens. Bone marrow and myelogram biopsy should be performed to exclude

[☆] How to cite this article: Muniz DN, Vasconcellos RC, Ambrosano L, Pereira ES. myeloid sarcoma on the scalp of a patient with acute myeloid leukemia. *An Bras Dermatol.* 2019;94:622–4.

^{☆☆} Study conducted at the Dermatology Outpatient Clinic of Hospital e Maternidade Celso Piirro, Pontifícia Universidade Católica de Campinas, Campinas, SP, Brazil.

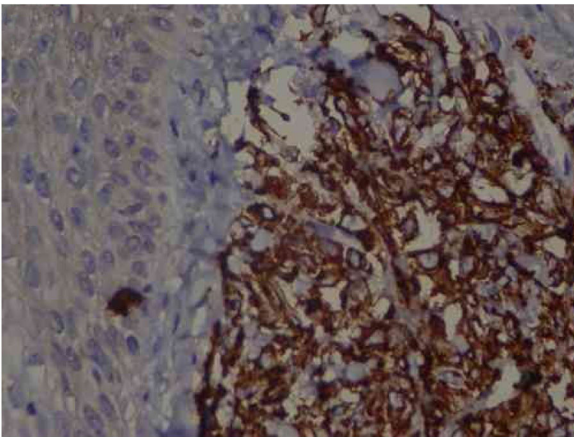


Figure 3 Immunohistochemistry: TCD4 diffuse positivity in 80% of lymphocytic infiltrate cells, focal positivity of 40% TCD3 cells, diffuse myeloperoxidase positivity in more than 90% of cells, TCD8 positivity in about 30% of cells, CD79a positivity in rare lymphoid cells of the dermis, Ki67 positivity in about 30% of the cells. $\times 40$ magnification.

other hematological malignancies. Many of the patients with myeloid sarcoma are misdiagnosed as having non-Hodgkin's lymphoma, Ewing's sarcoma, rhabdomyosarcoma, or neuroblastoma.³ Often, imaging tests, such as magnetic resonance imaging and computed tomography, should be used to elucidate the diagnosis when there is a central nervous system or musculoskeletal system impairment. Positron-emission tomography (PET) and computed tomography (CT) are used for radiotherapy planning and monitoring of therapeutic response. There are few studies regarding myeloid sarcoma, without consensus or protocols regarding treatment. There are also no prognostic studies. It is known that systemic and aggressive treatment is recommended for reducing the rate of progression to leukemia, using FLT 3 inhibitors, farnesyltransferase inhibitors, and histone deacetylase inhibitors.^{4,5}

An anatomopathological examination was performed (Fig. 2), which demonstrated a dense diffuse infiltration of lymphocytic cells, atypical and large cells, four-to-five times the usual size of mature lymphocytes, with bizarre formats and convoluted nuclei in the superficial, intermediate, and deep dermis, with extension to the hypodermis, sparing the epidermis. There was diffuse positivity for CD43 in 80% of lymphocytic infiltrate cells, diffuse myeloperoxidase positivity in more than 90% of cells, Ki67 positivity in about 30% of cells, and granzyme, alk1, CD3, CD20 and CD30 negativity. Therefore, the diagnosis of myeloid sarcoma was established. At the end of the chemotherapy, she presented total remission of the hematological alterations; however, as she maintained lesions on the scalp, she opted for retreatment with radiotherapy. However, the lesions remained unchanged and the patient evolved with relapse of myeloid leukemia, with a

new chemotherapy protocol initiated by the hematology team.

Funding

None declared.

Author's contribution

Débora Nogueira Muniz: Elaboration and writing of the manuscript; obtaining, analyzing and interpreting the data; critical review of the literature.

Renata Cristina Vasconcelos: Conception and planning of the study; obtaining, analyzing and interpreting the data; critical review of the literature; critical review of the manuscript.

Letícia Ambrosano: Approval of the final version of the manuscript; effective participation in research orientation; intellectual participation in propaedeutic and/or therapeutic conduct of the cases studied.

Elisangela Samartin Pegas Pereira: Approval of the final version of the manuscript; conception and planning of the study; effective participation in research orientation; intellectual participation in propaedeutic and/or therapeutic conduct of the cases studied; critical review of the manuscript.

Conflicts of interest

None declared.

Acknowledgements

Appreciate to the Department of Dermatology of the PUC hospital for allowing and making available the material necessary for its accomplishment.

References

1. Almond LM, Charalampakis M, Ford SJ, Gourevitch D, Desai A. Myeloid sarcoma: presentation, diagnosis and treatment. *Clin Lymphoma Myeloma Leuk.* 2017;17:263–7.
2. Yilmaz AF, Saydam G, Sahin F, Baran Y. Granulocytic sarcoma: a systematic review. *Am J Blood Res.* 2013;3:265–70.
3. Gupta AJ, Mandal S, Gupta R, Khurana N, Gulati A. Myeloid sarcoma presenting as nasal and orbital mass: an initial manifestation of an acute myeloid leukaemia. *J Clin Diagn Res.* 2017;11:ED24–6.
4. Katagiri T, Ushiki T, Masuko M, Tanaka T, Miyakoshi S, Fuse K, et al. Successful 5-azacytidine treatment of myeloid sarcoma and leukemia cutis associated with myelodysplastic syndrome: a case report and literature review. *Medicine (Baltimore).* 2017;96:e7975.
5. Kono M, Allen PK, Lin SH, Wei X, Jeter MD, Welsh JW, et al. Myeloid sarcoma on the scalp of a patient with acute myeloid leukemia. *J Thorac Oncol.* 2017;12:1696–703.

Débora Nogueira Muniz ^{a,*},
Renata Cristina Vasconcellos ^b, Leticia Ambrosano ^b,
Elisangela Samartin Pegas Pereira ^b

^a Medical Student, Pontifícia Universidade Católica de Campinas, Campinas, SP, Brazil

^b Dermatology Outpatient Clinic, Pontifícia Universidade Católica de Campinas, Campinas, SP, Brazil

* Corresponding author.

E-mail: debora.n.muniz@hotmail.com (D.N. Muniz).

Received 4 March 2018; accepted 23 October 2018

<https://doi.org/10.1016/j.abd.2019.09.001>
0365-0596/

© 2019 Published by Elsevier España, S.L.U. on behalf of Sociedade Brasileira de Dermatologia. This is an open access article under the CC BY license (<http://creativecommons.org/licenses/by/4.0/>).

Neurofibromatosis with vitiligo: an uncommon association rather than coexistence?^{☆,☆☆}

Dear Editor,

Type 1 neurofibromatosis (NF1) is an autosomal dominant multisystem disease caused by a mutation in the neurofibromin 1 gene which affects tissues derived from the neural crest.¹ Clinically, it is characterized by a spectrum of defects comprising of neural tumors, *café-au-lait* spots, intertriginous freckling, and skeletal defects. Generalized vitiligo has rarely been reported with neurofibromatosis. Here, we present two cases of NF1 associated with vitiligo and showing the halo phenomenon in neurofibromas.

A 28-year-old male patient who was a known case of NF1 presented with multiple depigmented patches on the skin, which had started developing in the last four years. His family history revealed that his mother also had neurofibromatosis, with no history of any depigmented lesions. Dermatological examination revealed multiple well-demarcated, light-brown macules of size varying from 5 to 50 mm present over the trunk, back, and upper limbs. Numerous sessile as well as pedunculated dome-shaped papulonodular lesions of varying sizes, suggestive of neurofibromas, were present over the face, trunk, back, and upper limbs. Some of these lesions were encircled by a depigmented halo. Sharply defined depigmented patches, consistent with a diagnosis of vitiligo and varying between 2 and 7 cm in size, were present over back, elbows, and dorsum of hands and feet (Fig. 1). Bilateral axillary freckling was also seen. Slit lamp examination of iris showed the presence of Lisch nodules. Dermoscopy of the vitiligo lesion showed reduced pigmentary network as compared to normal skin (Fig. 2).

The second case was a 35-year-old male patient; a known case of neurofibromatosis presented with depigmented patches involving the normal skin and the skin surrounding the neurofibromas over the previous year. There was a family history of neurofibromatosis in his father and

brother. On cutaneous examination, multiple dome-shaped, skin colored papulonodular lesions of variable sizes and soft in consistency were present over the face, trunk, back, and extremities. Some nodules had depigmented halo around them. Multiple well-demarcated, light brown colored patches, 5–20 mm in size, were present over back, chest and upper extremities. Sharply demarcated patches of depigmentation suggestive of vitiligo, along with freckles, were present in both the axilla and over the trunk and

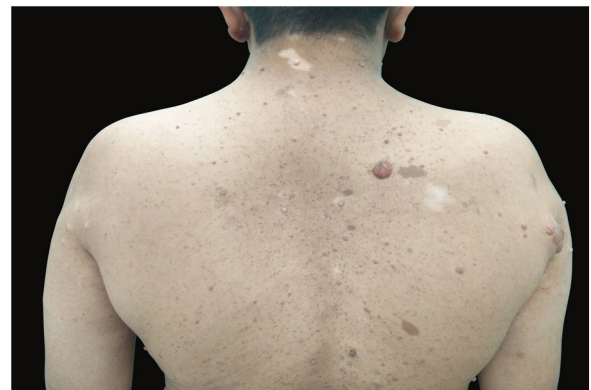

Figure 1 *Café-au-lait* macules, neurofibromas with perilesional halo, and vitiligo patches over the back.

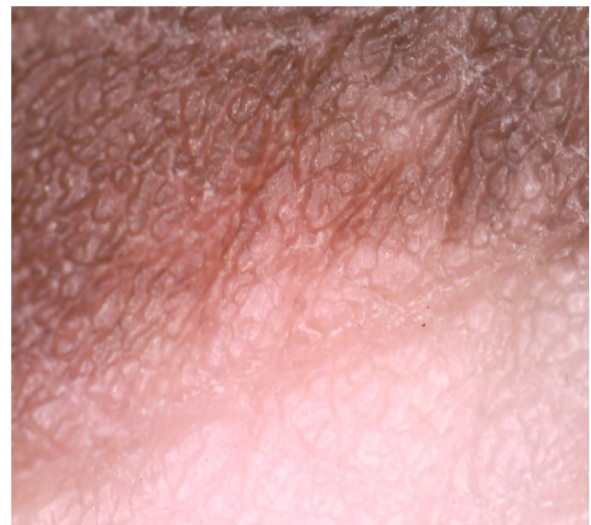

Figure 2 Border of a lesion on dermoscopy, showing reduced pigmentary network in the lesion compared to normal skin.

[☆] How to cite this article: Tandon S, Singh A, Arora P, Gautam RK. Neurofibromatosis with vitiligo: an uncommon association rather than coexistence? *An Bras Dermatol*. 2019;94:624–6.

^{☆☆} Study conducted at the Dermatology Department, Dr. Ram Manohar Lohia Hospital, New Delhi, India.