




- Murphey MD, Carroll JF, Flemming DJ, Pope TL, Gannon FH, Kransdorf MJ. From the archives of the AFIP: benign musculoskeletal lipomatous lesions. *Radiographics*. 2004;24:1433–66.
- Daubner D, Spieth S, Pablik J, Zöphel K, Paulus T, Laniado M. Hibernoma – two patients with a rare lipoid soft-tissue tumour. *BMC Med Imaging*. 2015;15:4.
- Shackelford RE, Al Shaarani M, Ansari J, Wei E, Cotelingam J. A twenty-four-year-old woman with left flank lipoma-like hibernoma. *Case Rep Oncol*. 2017;10:438–41.

Margarida Moura Valejo Coelho \*, Alexandre João , Cândida Fernandes 

Department of Dermatology and Venereology, Centro Hospitalar Universitário de Lisboa Central, Lisbon, Portugal

\* Corresponding author.

E-mail: [margarida.m.v.coelho@chlc.min-saude.pt](mailto:margarida.m.v.coelho@chlc.min-saude.pt) (M.M. Valejo Coelho).

Received 23 August 2018; accepted 6 November 2018

<https://doi.org/10.1016/j.abd.2019.09.018>  
0365-0596/

© 2019 Published by Elsevier España, S.L.U. on behalf of Sociedade Brasileira de Dermatologia. This is an open access article under the CC BY license (<http://creativecommons.org/licenses/by/4.0/>).

## Urticaria multiforme: a case report in an infant<sup>☆,☆☆</sup>

Dear Editor,

Urticaria multiforme (UM) is an uncommon benign cutaneous hypersensitivity that occurs mainly in pediatric patients.<sup>1,2</sup> It is characterized by annular lesions with a violaceous center, and may be accompanied by short-term fever, as well as by hand and foot edema.<sup>2,3</sup> It is a poorly recognized condition, mainly due to lack of reports in the literature. Furthermore, it is an important differential diagnosis for erythema multiforme.

A female infant was born at 31 weeks due to intrauterine growth restriction. After receiving the meningococcal and pneumococcal vaccines when she was 4 months old, annular macules with erythematous borders and red-frosted centers appeared (Fig. 1). The lesions presented an ephemeral character (24 h), with new macules appearing concomitantly. Due to age, it was not possible to evaluate pruritus. The diagnostic hypotheses were urticaria multiforme and childhood annular erythema. A biopsy was conducted, revealing preserved epidermis, a superficial and deep perivascular and interstitial inflammatory lymphohistiocytic infiltrate permeated with some eosinophils. There was no sign of vasculitis, corroborating with the diagnosis of urticaria multiforme (Figs. 2 and 3). Antihistamine treatment (hydroxyzine 0.5 mg/kg every 12 h) was started. After ten days, the condition resolved completely, without residual lesions.

Originally described in 1997 by Tamayo-Sanchez et al. under the name of acute annular urticaria,<sup>1</sup> it had its name changed to urticaria multiforme in 2007 due to clinical similarity with erythema multiforme,<sup>2</sup> as described by Shah et al., when the authors reported 19 of these cases. They also proposed that this condition is a variant of common urticaria, since the patients presented pruritus and dermatographism.<sup>1,2</sup>

With few cases in the literature, the etiology is poorly understood. In most cases there is a temporal relationship with infections (mycoplasma, adenovirus, streptococci, Epstein-Barr), medications (mainly antibiotics), and vaccinations. In 2016, Sempau et al. found an association with previous use of amoxicillin.<sup>3</sup> Specifically in neonates, there has been proven infection by herpes virus 6, and decreased viral load accompanied by clinical improvement of the patient.<sup>4</sup>

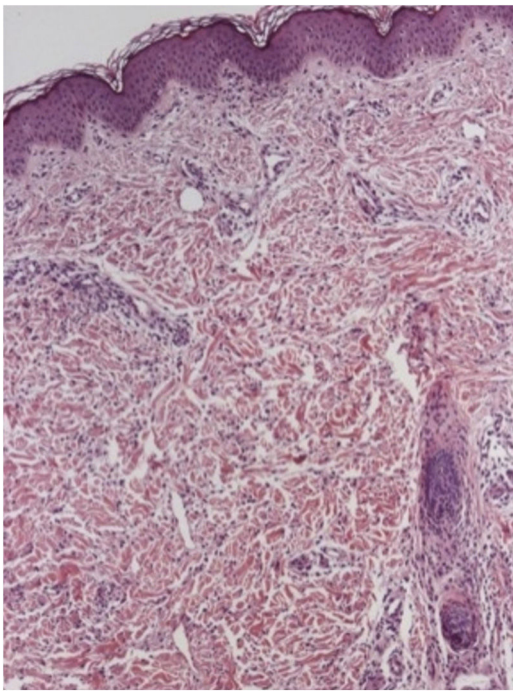
The most affected age range is between 4 months and 4 years, although newborns and adolescents may also develop the condition. Cutaneous lesions begin as urticarial lesions that rapidly expand in a centrifugal manner and become annular, forming coalescent polycyclic plaques with violet

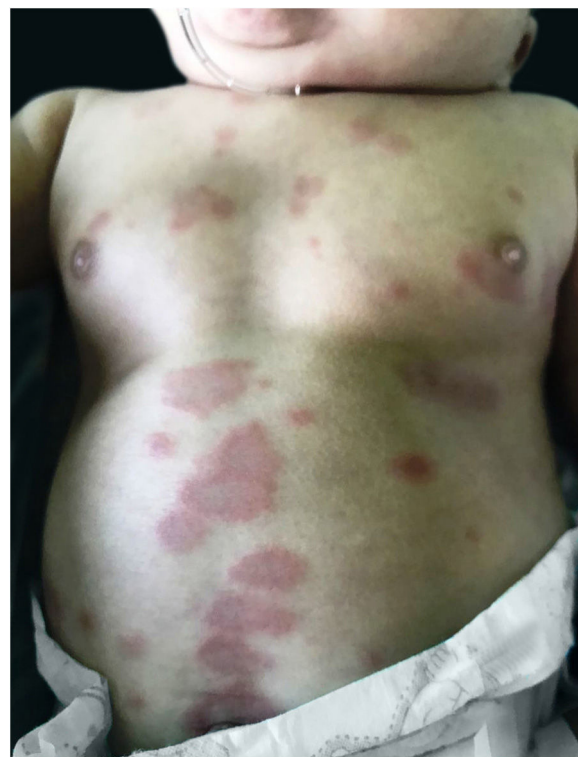

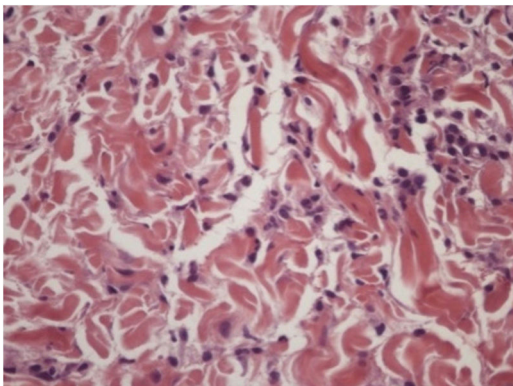
Figure 1 Erythematous annular plaques with lighter centers in the abdomen.

<sup>☆</sup> How to cite this article: Luce MCA, Souza BC, Camargo MFVC, Valente NYS. Urticaria multiforme: a case report in an infant. *An Bras Dermatol*. 2019;94:628–30.

<sup>☆☆</sup> Study conducted at the Hospital do Servidor Público Estadual de São Paulo, São Paulo, SP, Brazil.



**Figure 2** Inflammatory lymphocytic and histiocytic perivascular and interstitial infiltrate permeated with some eosinophils. Hematoxylin & eosin,  $\times 100$ .



**Figure 3** Interstitial histiocytic infiltrate with eosinophils. Hematoxylin & eosin,  $\times 400$ .

or opaque red centers. Individually, each lesion dissipates within 24 h. Edema of the hands, feet, and face are important clinical signs, present in 61% of cases.<sup>2</sup> The most present symptom is pruritus (94%); nonetheless, it can be difficult to evaluate in many young patients.<sup>2</sup> Fever and dermographism are present in 44% of the cases; however, the general condition is preserved.<sup>2</sup> The lesions resolve spontaneously within ten days without scars.

The diagnostic criteria are: annular, transitory, ecchymotic-center plaques, each lesion lasting less than 24 h, associated fever episode, total duration of the condition being less than ten days, and edema of the extremities.<sup>3</sup> Laboratory tests are not necessary, a good anamnesis and a dermatological physical examination are sufficient.

As in most cases the diagnosis is made clinically, the histopathological records are quite scarce. Findings of superficial dermal edema associated with perivascular and interstitial lymphocytic infiltrates with eosinophils and occasionally neutrophils predominate. In one of the cases reported by Samorano et al. there was presence of histiocytes, as well as in the report presented here, but this is not a common finding.<sup>5</sup>

The main differential diagnosis is erythema multiforme. Initially, many patients are mistakenly diagnosed with erythema multiforme and subsequently the diagnosis is corrected. Important clinical findings for differentiation are the rapid resolution of urticarial multiforme lesions (<24 h), and the presence of a necrotic center, which is present in erythema multiforme. Another differential diagnosis is acute urticaria, in which there is intense pruritus, but no fever, and the lesions do not have an equinox center.<sup>2</sup> In children with fever and acral face edema, it must be differentiated from a reaction similar to serum sickness, which occurs after administration of animal serum or foreign proteins. The most common clinical condition includes fever, arthralgia, angioedema, urticaria, and lymphadenopathy.<sup>2,3</sup> It can also present annular centrifugal erythema, migratory chronic erythema, viral rash, urticaria vasculitis, other vasculitis, and lupus erythematosus.

The treatment of urticaria multiforme is symptomatic, since there is spontaneous resolution in most cases, as seen in the patient of this report. Any suspected and unnecessary medications should be discontinued.<sup>1</sup> Systemic antihistamines should be prescribed to relieve symptoms. In refractory and severe cases, the use of systemic corticosteroids in combination with antihistamines may be necessary.<sup>2,3,5</sup>

### Financial support

None declared.

### Author's contribution

Maria Claudia Alves Luce: Conception and planning of the study; elaboration and writing of the manuscript; critical review of the literature.

Bruno de Castro e Souza: Conception and planning of the study; elaboration and writing of the manuscript; critical review of the literature.

Maria Fernanda Vieira Cunha Camargon: Approval of the final version of the manuscript; intellectual participation in propaedeutic and/or therapeutic conduct of the cases studied; critical review of the manuscript.

Neusa Yuriko Sakai Valente: Approval of the final version of the manuscript; intellectual participation in propaedeutic and/or therapeutic conduct of the cases studied; critical review of the manuscript.

### Conflicts of interest





None declared.

## Acknowledgements

Special thanks to Dr. Maria Fernanda Camargo and Dr. Neusa Valente for their collaboration on this manuscript, and to the entire HSPE team.

## References

1. Tamayo-Sanchez L, Ruiz-Maldonado R, Laterza A. Acute annular urticaria in infants and children. *Pediatr Dermatol*. 1997;14:231–4.
2. Shah KN, Honig PJ, Yan AC. Urticaria multiforme: a case series and review of acute annular urticarial hypersensitivity syndromes in children. *Pediatrics*. 2007;119:e1177–83.
3. Sempau L, Martín-Sáez E, Gutiérrez-Rodríguez C, Gutiérrez-Ortega MC. Urticaria multiforme: a report of 5 cases and review of the literature. *Actas Dermosifiliogr*. 2016;107:e1–5.
4. Borghesi A, Cipelletti P, Maragliano R, Manzoni P, Stronati M. Human herpesvirus-6 associated neonatal urticaria multiforme. *Arch Dis Child Fetal Neonatal Ed*. 2013;98:F450.
5. Samorano LP, Fernandez VV, Valente NY, Arnone M, Nico MM, Rivitti-Machado MC, et al. Urticaria multiforme: two cases with histopathological findings. *Allergol Int*. 2017;66:154–5.

Maria Claudia Alves Luce  <sup>a,\*</sup>,  
Bruno de Castro e Souza  <sup>a</sup>,  
Maria Fernanda Vieira Cunha Camargo  <sup>b</sup>,  
Neusa Yuriko Sakai Valente  <sup>c</sup>

<sup>a</sup> Department of Dermatology, Hospital do Servidor Estadual de São Paulo, São Paulo, SP, Brazil

<sup>b</sup> Department of Pediatric Dermatology, Hospital do Servidor Público Estadual de São Paulo, São Paulo, SP, Brazil

<sup>c</sup> Department of Dermatopathology, Hospital do Servidor Público Estadual de São Paulo, São Paulo, SP, Brazil

\* Corresponding author.

E-mail: [mcluce@gmail.com](mailto:mcluce@gmail.com) (M.C. Luce).

Received 24 April 2018; accepted 8 November 2018

<https://doi.org/10.1016/j.abd.2019.09.005>  
0365-0596/

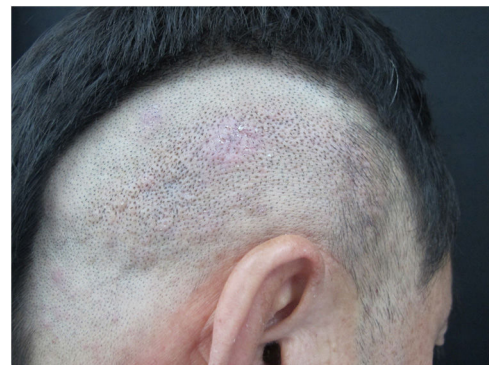© 2019 Published by Elsevier España, S.L.U. on behalf of Sociedade Brasileira de Dermatologia. This is an open access article under the CC BY license (<http://creativecommons.org/licenses/by/4.0/>).

## Multiple warty dyskeratoma on the scalp<sup>☆,☆☆</sup>

Dear Editor,

We report a case of multiple warty dyskeratoma (WD). The patient is a 55-year-old Chinese man who presented with a four-year history of multiple pruritic papules and plaques on the scalp. The number and size of the lesions were gradually increasing. No family history of similar lesions was recorded. Physical examination revealed multiple, discrete, hyperkeratotic papules and plaques, but no vesicles or erosions on his scalp (Fig. 1). No other abnormal systemic involvements were found in our case. Biopsy from multiple lesions revealed similar findings, appearing as cup-shaped invaginations filled with keratotic plugs and acantholytic dyskeratotic architecture covered with a fibrotic capsule in the dermis. The invaginations contain numerous clefts and acantholytic dyskeratotic cells located in the lower epidermis (Fig. 2A). Villi lined by a single layer of basaloid cells and typical corps ronds in the thickened granular layer were observed, with moderate inflammatory infiltrate consisting of lymphocytes, histiocytes, and plasma cells in the dermis. It is worth noting that one cyst contains acantholytic dyskeratotic cells in a hair follicle (Fig. 2B). Based on these clinical and histological findings, a diagnosis of multiple WD was made. WD was first described by Szymanski in 1957.<sup>1</sup> It is a relatively uncommon benign skin condition which frequently arises as a solitary lesion with a central keratotic plug on sun-

exposed sites in the older adults. It is usually localized on the scalp, face, or neck, but has occasionally been reported on oral and vulvar mucosae. Multiple WDs are very rare and only six reported cases were retrieved from PubMed. Most were female and two cases had renal dysfunction.<sup>2</sup> The previously reported lesions were asymptomatic or associated with only mild pruritus. Recently, Xie et al. reported a case with severe pruritus and the infiltration of eosinophilic granulocytes seen on histologic examination.<sup>3</sup> Microscopically, no eosinophils were observed in our patient, and only mild itching was present. In our male patient, many violaceous, hyperkeratotic plaques on the scalp can be observed, which is different from previously reported cases with papules or nodules. WD had been proposed to originate from the hair follicle or connection to the sebaceous glands. In our patient, cup-shaped invaginations filled with keratotic plugs and acantholytic dyskeratotic cells were located in hair follicles, which supported its association with hair follicle unit.



**Figure 1** Multiple, firm, violaceous, hyperkeratotic plaques and nodules on the scalp.

<sup>☆</sup> How to cite this article: Zhao Q, Zhou H, Geng S. Multiple warty dyskeratoma on the scalp. *An Bras Dermatol*. 2019;94:630–1.

<sup>☆☆</sup> Study conducted at the Second Affiliated Hospital, Xi'an Jiaotong University, Shaanxi Province, China.