





1. Peckruhn MD, Tittelbach J, Elsner P. Update: treatment of necrobiosis lipoidica. *J Dtsch Dermatol Ges.* 2017;15:151–7.
2. Hammami H, Youssef S, Jaber K, Dhaoui MR, Doss N. Perforating necrobiosis lipoidica in a girl with type 1 diabetes mellitus: a new case reported. *Dermatol Online J.* 2008;14:11.
3. Zhang KS, Quan LT, Hsu S. Treatment of necrobiosis lipoidica with etanercept and adalimumab. *Dermatol Online J.* 2009;15:12.
4. Chung CG, Rosengrant A, Helm KF, Shupp DL. Necrobiosis lipoidica occurring in a patient with rheumatoid arthritis on concurrent tumor necrosis factor- α inhibitor therapy. *Int J Dermatol.* 2015;54:1294–6.
5. Leister L, Körber A, Dissemmond J. Successful treatment of a patient with ulcerated necrobiosis lipoidica non diabeticorum with adalimumab. *Hautarzt.* 2013;64:509–11.

Alexandra Brugnera Nunes de Mattos ^{a,*},
 Carolina Finardi Brummer ^a,
 Gabriela Di Giunta Funchal ^b,
 Daniel Holthausen Nunes ^c

^a *Dermatology Service of the Hospital Universitário Polyodoro Ernani de São Thiago, Universidade Federal de Santa Catarina, Florianópolis, SC, Brazil*

^b *Pathology and Dermatology Service of the Hospital Universitário Polyodoro Ernani de São Thiago, Department of Pathology of Universidade Federal de Santa Catarina, Florianópolis, SC, Brazil*

^c *Dermatological Medical Residency Program in Dermatology of the Hospital Universitário Polyodoro Ernani de São Thiago, Universidade Federal de Santa Catarina, Florianópolis, SC, Brazil*

*Corresponding author.

E-mail: anunes12@hotmail.com (A.B. Nunes de Mattos).

Received 23 August 2018; accepted 18 April 2019;

Available online 4 November 2019

<https://doi.org/10.1016/j.abd.2019.04.003>

0365-0596/ © 2019 Sociedade Brasileira de Dermatologia.

Published by Elsevier España, S.L.U. This is an open access article under the CC BY license (<http://creativecommons.org/licenses/by/4.0/>).

Squamous cell carcinoma of the vulva diagnosed by a dermatologist^{☆,☆☆}

Dear Editor,

Vulvar cancer is considered a rare disease, accounting for approximately 4% of all female genital neoplasms, and squamous cell carcinoma is the most prevalent, accounting for 90% of malignant tumors in this region, followed by melanoma. Its incidence is higher in the elderly population, with a worldwide incidence of approximately 1.8/100,000 women, increasing to 20/100,000 after the age of 75 years.^{1–4}

A female patient, 82 years old, from Bauru-SP, was referred to the dermatology department with complaint of pruritus and a lesion in the genital region two months previously. Hypertension, hypothyroidism, and diabetes were reported as comorbidities. Widowed 14 years ago, she denied sexual activity ever since.

On examination of the genital region, erythema and edema of the entire labia majora were found, and an ulcerative nodule approximately 1.7 cm in diameter was found in the region of the labia minora (Fig. 1).

An incisional biopsy was performed, showing a well-differentiated, invasive, ulcerated squamous cell carcinoma (Fig. 2). HPV screening for genome amplification was negative (Table 1). The patient was referred to the oncology department for treatment at a referral hospital.

Squamous cell carcinoma of the vulva usually presents as a solitary nodule or ulcer on the labia majora or minora, with associated pain, bleeding, itching, odor, or discharge. Among the causative factors involved in its pathogenesis are smoking, HPV infection, and precursor lesions such as lichen-sclerotic atrophy and incipient vulvar carcinomas – now called vulvar intraepithelial neoplasms – also related to HPV.²

Morphological variants have been described, including basaloid and verrucoid subtypes, which are related to viral infection and are more common in the young population, whereas keratinizing variants tend to be HPV-negative and occur in elderly women.¹

The staging is performed by the TNM system. Tumors diagnosed early, up to stage T1a, can be treated only with resection of the lesion with at least 1 cm of margin, with survival rates at five and ten years around 100% and 94.7%, respectively. From the T1b stage, tumors from 2 cm with stromal invasion of at least 1 mm may require partial or total vulvectomy, with ipsilateral or bilateral lymph node dissection. Since lymphatic dissemination is the most important prognostic factor, histopathological study of regional lymph nodes is essential in cases of invasive tumors. If lymph node invasion is confirmed, chemotherapy and additional radiation therapy may be required.^{3,5}

Treatment in the early stages has better results, both esthetic-functional and in terms of overall survival, presenting a high cure rate; however, it occurs in a very low percentage of women affected, since in general they seek medical services late and professionals delay in making the diagnosis.

The dermatological literature lacks of scientific articles of the neoplasms of the female genital epithelium; the present report attempts to demonstrate the importance of the anamnesis and the dermatological examination of this anatomical region in order to make an early diagnosis.

[☆] How to cite this article: Michels IB, Tonello CS, Soares CT. Squamous cell carcinoma of the vulva diagnosed by a dermatologist. *Am Bras Dermatol.* 2019;94:771–2.

^{☆☆} Study conducted at the Instituto Lauro de Souza Lima, Bauru, SP, Brazil.

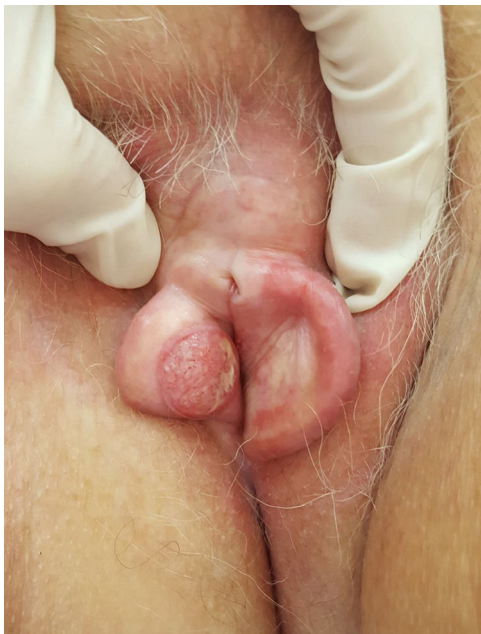

Figure 1 Ulcerated nodular tumor infiltrating the labia minora.

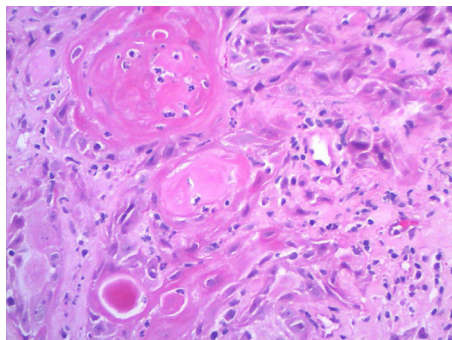


Figure 2 Blocks of atypical epithelial cells with corneal pearl formation (Hematoxylin & eosin, $\times 200$).

Table 1 HPV screening by genome amplification.

Target sequences tested	Result
HPV SOE (184 pb)	Negative
HPV 6 (118 pb)	Negative
HPV 11 (120 pb)	Negative
HPV 16 (137 pb)	Negative
HPV 18 (121 pb)	Negative

Financial support

None declared.

Authors' contribution

Isadora Barreto Michels: Conception and planning of the study; composition of the manuscript; collection, analysis, and interpretation of data; critical review of the literature.

Cláudio Sampieri Tonello: Approval of the final version of the manuscript; participation in the design of the study; intellectual participation in the propaedeutic and/or therapeutic conduct of the studied cases; critical review of the manuscript.

Cleverson Teixeira Soares: Approval of the final version of the manuscript; collection, analysis, and interpretation of data.

Conflicts of interest

None declared.

Acknowledgment

To the preceptors Cláudio Sampieri Tonello and Cléverson Teixeira Soares.

References

1. Winkinson EJ, Teixeira MR. Tumours of the vulva. In: World Health Organization Classification of Tumours. Pathology and genetics of tumours of the breast and female genital organs. Lyon: IARC Press; 2003. p. 311–6.
2. Pinto AP. Etiopatogenia do câncer vulvar. *J Bras Patol Med Lab.* 2002;38:55–63.
3. Rakislova N, Clavero O, Alemany L, Saco A, Quirós B, Lloveras B, et al. Histological characteristics of HPV-associated and -independent squamous cell carcinomas of the vulva: a study of 1594 cases. *Int J Cancer.* 2017;141:2517–27.
4. Faber MT, Sand FL, Albieri V, Norrild B, Kjaer SK, Verdoodt F. Prevalence and type distribution of human papillomavirus in squamous cell carcinoma and intraepithelial neoplasia of the vulva. *Int J Cancer.* 2017;141:1161–9.
5. Federação Brasileira das Associações de Ginecologia e Obstetrícia; Sociedade Brasileira de Cancerologia. Diretrizes Clínicas na Saúde Suplementar: câncer de vulva. [place unknown]: Associação Médica Brasileira e Agência Nacional de Saúde Suplementar; 2011.

Isadora Barreto Michels ^{a,*},
Cláudio Sampieri Tonello ^a,
Cleverson Teixeira Soares ^b

^a Department of Dermatology, Instituto Lauro de Souza Lima, Bauru, SP, Brazil

^b Department of Pathology, Instituto Lauro de Souza Lima, Bauru, SP, Brazil

* Corresponding author.

E-mail: ibmichels@hotmail.com (I.B. Michels).

Received 1 January 2019; accepted 29 April 2019;
Available online 6 November 2019

<https://doi.org/10.1016/j.abd.2019.04.005>

0365-0596/ © 2019 Sociedade Brasileira de Dermatologia.

Published by Elsevier España, S.L.U. This is an open access article under the CC BY license (<http://creativecommons.org/licenses/by/4.0/>).