

Authors' contributions

Deborah Lucena Markman: approval of the final version of the manuscript; elaboration and writing of the manuscript; effective participation in research orientation; critical review of the literature.

Pamella Paola Bezerra de Oliveira: elaboration and writing of the manuscript; critical review of the literature.

Daniela Mayumi Takano: approval of the final version of the manuscript; effective participation in research orientation; critical review of the manuscript.

Idalina Inês Fonseca Nogueira Cambuim: approval of the final version of the manuscript; effective participation in research orientation; critical review of the manuscript.

Conflicts of interest

None declared.

References

1. Queiroz JPAF, Sousa FDN, Lage RA, Izael MA, Santos AG. Criptococose-uma revisão bibliográfica. *Acta Vet Bras.* 2008;2:32–8.
2. Azulay RD, Azulay DR, Abulafia LA. *Dermatologia.* 6th ed. Rio de Janeiro: Guanabara Koogan; 2013.
3. Bivanco FC, Machado CDS, Martins EL. Criptococose cutânea. *Arq Med ABC.* 2006;31:102–9.

4. Pinto Junior VL, Galhardo MCG, Lazéra M, Wanke B, Reis RS, Perez M. Criptococose associada à AIDS. A importância do cultivo da urina no seu diagnóstico. *Rev Soc Bras Med Trop.* 2006;39:230–2.
5. Trope BM, Fernandes ALC, Maceira MHJP, Barreiros MGC. Paniculite criptocócica em transplantado renal. *An Bras Dermatol.* 2008;83:233–6.

Deborah Lucena Markman ^{a,*},
Pamella Paola Bezerra de Oliveira ^a,
Daniela Mayumi Takano ^b,
Idalina Inês Fonseca Nogueira Cambuim ^c

^a Department of Dermatology, Hospital Otávio de Freitas, Recife, PE, Brazil

^b Department of Pathology, Universidade Federal de Pernambuco, Recife, PE, Brazil

^c Mycology Laboratory, Hospital Otávio de Freitas, Recife, PE, Brazil

* Corresponding author.

E-mail: deborahlmarkman@gmail.com (D.L. Markman).

Received 27 May 2018; accepted 4 July 2019

Available online 18 March 2020

<https://doi.org/10.1016/j.abd.2019.07.009>

0365-0596/ © 2020 Published by Elsevier España, S.L.U. on behalf of Sociedade Brasileira de Dermatologia. This is an open access article under the CC BY-NC-ND license (<http://creativecommons.org/licenses/by-nc-nd/4.0/>).

Terra firma-forme dermatosis: an underdiagnosed condition ☆☆☆



Dear Editor,

A 12-year-old girl, who had no co-morbidities, sought dermatological care due to the emergence of brownish spots that looked like “dirt”, which were spread through the body and had progressively evolved in the previous two years. This condition caused great social impact to the patient, given that she suffered from discrimination at school. She had used ketoconazole cream as prescribed by a physician of the Basic Health Unit; however, there was no clinical response. The patient noticed that the lesions became discreetly clearer after intense rubbing with gauze, but without improvement after washing with soap and water.

The dermatological examination indicated that the patient had hyperkeratotic brownish plaques with a dotted pattern, affecting the neck, back, abdomen, and, in a less evident manner, the lower limbs (Figs. 1 and 2). After suspecting the presence of terra firma-forme, the lesions were

rubbed with gauze embedded in 70% alcohol and the plaques were removed (Fig. 3).

“Terra firma-forme” is a Latin expression, which means “solid earth”, also known as Duncan’s dirty dermatosis. It is a benign and idiopathic skin disorder that was described in 1987.^{1–3} Its prevalence and incidence are unknown, because it is an underdiagnosed disorder.¹ The cases described in the literature have indicated greater involvement during childhood and adolescence.^{2,3}

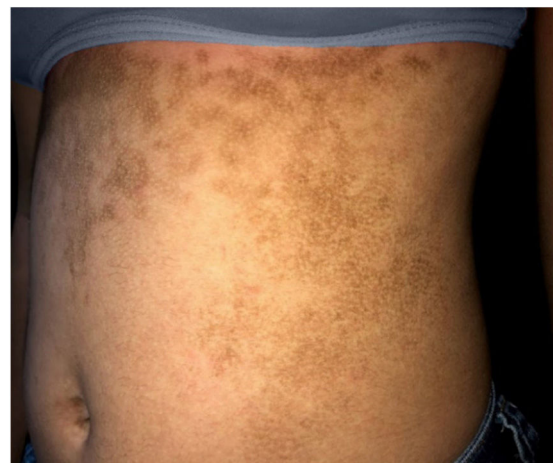

Figure 1 Hyperkeratotic brownish plaques with a dotted pattern affecting the abdomen.

☆ How to cite this article: Badaró BA, Diniz LM, Nogueira PSE. Terra firma-forme dermatosis: an underdiagnosed condition. *An Bras Dermatol.* 2020;95:397–8.

☆☆ Study conducted at the Hospital Universitário Cassiano Antônio Moraes, Vitória, ES, Brazil.

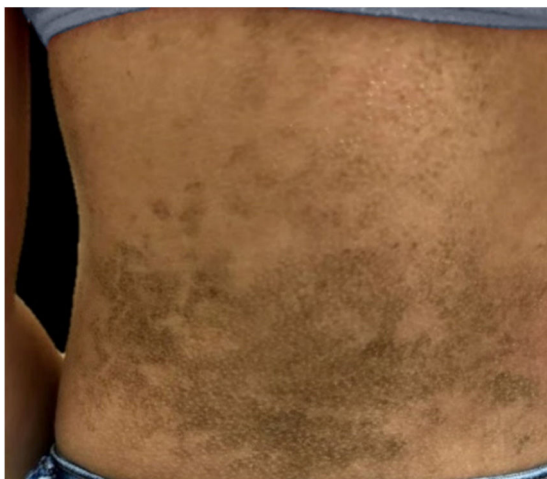

Figure 2 Hyperkeratotic brownish plaques with a dotted pattern affecting the back.

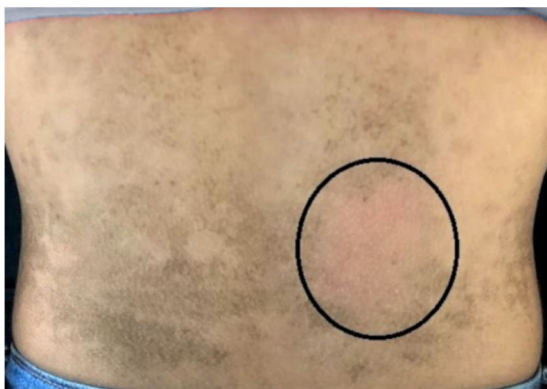


Figure 3 Area without lesions after rubbing the skin with gauze embedded in 70% alcohol.

The pathogenesis is uncertain; however, it is attributed to disturbance in the maturation of keratinocytes, leading to the compaction of these cells, associated with melanin, sebum, and microorganisms in the epidermis.¹⁻³ This fact explains the hyperkeratosis and hyperpigmentation clinically observed.

This dermatosis is characterized by slightly elevated, brownish or blackened, hyperkeratotic, and asymptomatic plaques and papules. The lesions are typically located in the neck, face, and trunk, bilaterally or unilaterally. It affects patients with adequate hygiene habits, and the lesions are not removed by washing with soap and water.^{1,2}

When the presence of the condition is suspected, dermatoscopy helps by detecting brownish polygonal plates arranged in a mosaic pattern.^{2,3} The diagnosis is confirmed by removing the affected area by firmly and persistently rubbing the skin with cotton soaked in 70% isopropyl alcohol.¹⁻⁴ This procedure possibly determines protein denaturation, interfering in the cell metabolism and diluting lipoprotein membranes,⁵ thus avoiding blood tests and skin biopsies.⁴ Histological evaluation is unnecessary; however, if performed, it can indicate acanthosis, papillomatosis, and lamellar hyperkeratosis.³

Differential diagnoses are made with hyperpigmented lesions, including confluent and reticulated papillomatosis of Gougerot and Carteaud, which has some similar characteristics and is considered a superficial variant of that dermatosis. It is possible to differentiate them by removing the lesions with alcohol in terra firma-forme dermatosis, in addition to considering other clinical findings, such as for example, acanthosis nigricans, which is a skin disorder usually associated with metabolic disorders and dermatitis neglecta, easily washed with soap and water,⁴ among others.^{1,2}

The treatment consists of the application of 70% isopropyl alcohol; however, the lesions may recur.¹⁻⁴ The skin should be washed with soap and water after using alcohol, taking into account the possible symptoms of intoxication as drowsiness, lethargy, respiratory depression, mucosal irritation, and others, especially in children. Absorption through the intact skin surface is low; however, it may increase after prolonged exposure.⁵ There is a report of the use of 5% salicylic acid once a day with a good response after two weeks.³

The patients and families should be advised to clean the skin at home,¹ in addition to the application of emollients for preventing xerosis caused by recurrent use of alcohol.²

It is important to recognize this dermatosis in order to avoid incompatible diagnostic and therapeutic procedures, as well as to reassure adolescents and family members, thus reducing social impact on patients' lives.

Financial support

None declared.

Authors' contributions

Bruna Anjos Badaró: Conception and planning of the study; elaboration and writing of the manuscript; obtaining, analysis, and interpretation of the data; intellectual participation in the propaedeutic and/or therapeutic conduct of the studied cases; critical review of the literature; critical review of the manuscript.

Lucia Martins Diniz: Approval of the final version of the manuscript; conception and planning of the study; effective participation in research orientation; intellectual participation in the propaedeutic and/or therapeutic conduct of the studied cases; critical review of the literature; critical review of the manuscript.

Paulo Sergio Emerich Nogueira: Intellectual participation in the propaedeutic and/or therapeutic conduct of the studied cases; critical review of the literature.

Conflicts of interest

None declared.

References

1. Singla C, Budhwar J, Mahajan BB. Bilaterally symmetrical terra firma-forme dermatosis: a diagnostic conundrum. *Egypt J Dermatol Venerol*. 2018;38:46-8.

2. Stiube A, Jenni D, Wiederkehr L, Anzengruber F, Nobbe S. Terra firme-forme dermatosis diagnostic sign and treatment: a case report. *Case Rep Dermatol.* 2019;11:108–12.
3. Vakirlis E, Theodosiou G, Lallas A, Apalla Z, Sotiriou E. Terra firma-forme dermatosis: differential diagnosis and response to salicylic acid therapy. *Pediatr Dermatol.* 2019;00:1–4.
4. Sasaya EMK, Ghislandi C, Trevisan F, Ribeiro TO, Mulinari-Brenner F, Gaiowski CB. Dermatitis neglecta. *An Bras Dermatol.* 2015;90(S1):58–60.
5. National Center for Biotechnology Information. PubChem Compound Database [Internet]. US: National Library of Medicine. Available from: <https://pubchem.ncbi.nlm.nih.gov/compound/3776> [cited 16.02.19].

Bruna Anjos Badaró *, Lucia Martins Diniz , Paulo Sergio Emerich Nogueira 

Service of Dermatology, Hospital Universitário Cassiano Antônio Moraes, Universidade Federal do Espírito Santo, Vitória, ES, Brazil

* Corresponding author.

E-mail: brunaanjosbadaro@hotmail.com (B.A. Badaró).

Received 28 February 2019; accepted 17 July 2019

Available online 20 March 2020

<https://doi.org/10.1016/j.abd.2019.07.013>

0365-0596/ © 2020 Sociedade Brasileira de Dermatologia.

Published by Elsevier España, S.L.U. This is an open access article under the CC BY license (<http://creativecommons.org/licenses/by/4.0/>).

Inflammatory segmental vitiligo during oral isotretinoin use: a casual association? ☆☆☆



Dear Editor,

Segmental vitiligo (SV) accounts for 3–20% of all cases of vitiligo and is usually not associated with autoimmune diseases when compared to non-segmental vitiligo (NSV).¹ Among the theories proposed for the pathophysiology of SV, it is essential to emphasize the presence of an autoimmune attack against a mosaic area.¹

In the literature, there are few reports on the emergence of vitiligo as a side effect of medications, especially oral isotretinoin. The objective of the present report is to demonstrate a possible new side effect of this medication since there are no descriptions of its association with SV in the literature.

A 17 year-old male patient, previously healthy and without a family history of vitiligo, was diagnosed with resistant acne, previously treated with topical and systemic antibiotic therapy. During the fifth month of treatment with oral isotretinoin (0.4 mg/kg/day, cumulative dose of 5.400 mg), there were a chromic spots surrounded by an erythematous-scaling halo in malar and perioral areas, not exceeding the mid line on the right side of the face (Fig. 1). Wood's light examination revealed fluorescent chalky white aspect, as well as polios is in beard hair (Fig. 2) favoring the SV diagnosis. After the withdrawal of isotretinoin, the patient began treatment with 0.1% tacrolimus ointment twice daily with an improvement of perilesional erythema after two months, although without improvement of achromy. Subsequently, it was submitted to 20 sessions of UVB-NB phototherapy, with little perifollicular pigmentation.

In the literature review, only three cases of vitiligo in the context of oral isotretinoin use are described. One report

describes the case of a patient who developed vitiligo during the use of oral isotretinoin at a dose of 0.3–0.4 mg/kg/day for the treatment of moderate to severe acne.² In another report, acrofacial vitiligo was developed only two months after the end of treatment with isotretinoin, which reduces the probability of a cause-and-effect relationship.³ There is also a report of worsening of NSV lesions in the lower lip and lower perioral region after chronic cheilitis due to the use of oral isotretinoin; a condition attributed in this case to the Koebner phenomenon.⁴

The mechanism of action of isotretinoin in this presumed association is not yet fully elucidated, but the drug appears to play a role in triggering autoimmunity in genetically susceptible individuals.⁵ Several reports of autoimmune diseases such as diabetes, autoimmune hepatitis, Guillain-Barré syndrome, and thyroiditis have been reported after the end of the isotretinoin regimen or during the last week of treatment.⁵ Besides, in vitro studies have also demonstrated that retinoid may have a pro-apoptotic effect on melanocytes.³

Although the cause-effect relationship of this association has not yet been proven, the increasing appearance of new cases in the literature is a warning sign for dermatologists to keep vigil on this possible new side effect.

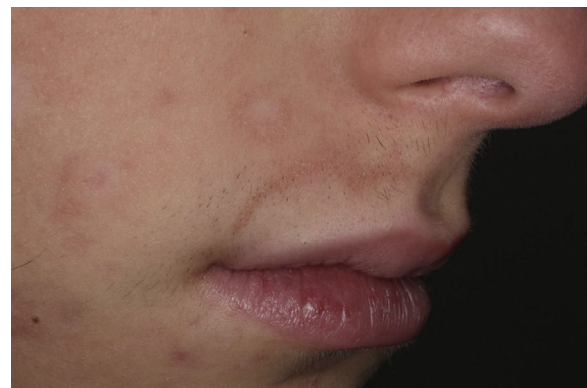

Figure 1 Achromic spots surrounded by halo erythematous and polios is in beard hairs in the malar and right perioral regions.

☆ How to cite this article: Avelar-Caggiano MFS, Castro CCS, Delatorre G. Inflammatory segmental vitiligo during oral isotretinoin use: a casual association? *An Bras Dermatol.* 2020;95:399–400.

☆☆ Study conducted at the Hospital Santa Casa de Misericórdia de Curitiba, Paraná, PR, Brazil.