

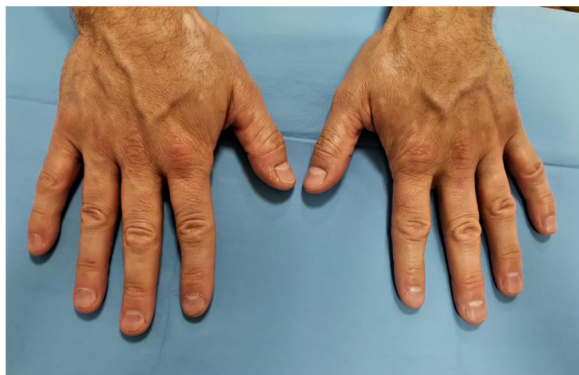## CASE LETTER

### Onset of vitiligo in a patient with acquired secondary hypogonadism under treatment with testosterone gel 2%: inside the pathogenesis☆☆☆



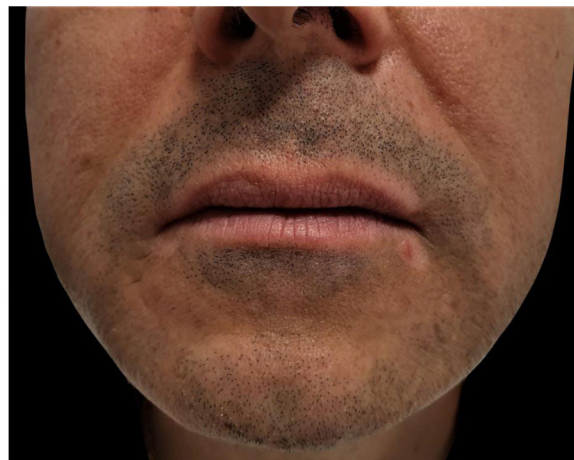
Dear Editor,

A 61-year-old man presented with a three-month history of symmetric depigmented lesions on the hands and perilabial region (Figs. 1 and 2). No other anatomical area was



**Figure 1** Symmetric macules of vitiligo on the dorsomedial part of the hands.

involved. Under Wood's light the lesions appeared bright white and sharply demarcated, confirming the diagnosis of vitiligo. His personal and family medical history was negative for autoimmune disorders. The patient reported that eight months before, a diagnosis of acquired secondary idiopathic hypogonadism due to aging was made (low levels of testosterone; normal LH and FSH levels; negative MRI of the hypothalamic-pituitary region and normal body mass index). Laboratory investigations and analysis of autoimmunity showed no alterations. Thyroid function was normal and thyroid antibodies were absent. According to this diagno-



**Figure 2** Perilabial depigmentation.

sis, he started treatment with topical testosterone 2% gel once a day for six months, which he applied at level of the chest and thighs. He noticed the first depigmentation area on the hands, during the fourth month of treatment. For vitiligo areas, pimecrolimus 1% cream was prescribed. After six months of follow-up, the treated vitiligo areas are stable and no further depigmented areas arose. The patient continues to perform the endocrinological consultations with good hormonal compensation.

The etiology of vitiligo is still unclear.<sup>1</sup> Several hypotheses have been proposed to explain the causes of melanocyte dysfunction.<sup>1</sup> In this regard, Kotb et al. also investigated the hormonal theory.<sup>1</sup> Specifically, they found a significant decrease in testosterone levels in the serum of males in both active and stable vitiligo groups when compared to controls, and in the active vitiligo group compared to the stable vitiligo group; besides, they did not find significant difference in testosterone levels between males and females in the active vitiligo group.<sup>1</sup> Furthermore, testosterone can be also involved in the downregulation of the inflammation. Indeed, testosterone suppresses immunity, affecting T-cell immunity by inhibiting T-helper 1 differentiation, justifying the sex differences in the response to viruses and autoimmunity.<sup>2</sup> All these findings confirm that hypogonadism may explain the predisposition for the onset of vitiligo in the present patient.

Drug-induced vitiligo is a rare side effect of several systemic and topical drugs.<sup>3</sup> In these cases, skin depigmentation is indistinguishable from vitiligo and appears to be

☆ How to cite this article: Paolino G, Bearzi P, Mercuri SR. Onset of vitiligo in a patient with acquired secondary hypogonadism under treatment with testosterone gel 2%: inside the pathogenesis. An Bras Dermatol. 2020;95:661–2.

☆☆ Study conducted at the IRCCS Ospedale San Raffaele, Milan, Italy.

due to activation of melanocyte-specific autoimmunity; for these reasons, this phenomenon should be known as “drug-induced vitiligo”, rather than with the less accurate term “drug-induced depigmentation”.<sup>4</sup> Goldstein et al. reported that testosterone may interact with tyrosine hydroxylase activity; besides, it is known that agents that interact with tyrosinase activity can paradoxically disrupt melanin production, by inducing the cellular stress response with inflammation and autoimmune destruction of melanocytes.<sup>5</sup> However, to date, there is no evidence of testosterone-induced vitiligo.

As far as the authors know, the present case represents the first clinical confirmation of the onset of vitiligo in a patient with hypogonadism, supporting the thesis that hypogonadism can be associated with vitiligo. At the same time, there is insufficient evidence to support a role of testosterone replacement therapy in the development of vitiligo. Indeed, no areas of depigmentation were observed at the testosterone application sites (chest and thighs). Further studies are needed to investigate the role of testosterone in pigmentation, also extending the research to possible new therapeutic implications.

### Financial support

None declared.

### Authors' contributions

Giovanni Paolino: Drafting and editing of the manuscript; intellectual participation in the propaedeutic and/or therapeutic conduct of the studied cases; critical review of the literature; critical review of the manuscript.

Pietro Bearzi: Drafting and editing of the manuscript; intellectual participation in the propaedeutic and/or therapeutic conduct of the studied cases; critical review of the literature; critical review of the manuscript.

Santo Raffaele Mercuri: Approval of the final version of the manuscript; intellectual participation in the propaedeutic and/or therapeutic conduct of the studied cases; critical review of the literature; critical review of the manuscript.

### Conflicts of interest

None declared.

### References

1. Kotb El-Sayed MI, Abd El-Ghany AA, Mohamed RR. Neural and endocrinal pathobiochemistry of vitiligo: comparative study for a hypothesized mechanism. *Front Endocrinol (Lausanne)*. 2018;9:197.
2. Kissick HT, Sanda MG, Dunn LK, Pellegrini KL, On ST, Noel JK, et al. Androgens alter T-cell immunity by inhibiting T-helper 1 differentiation. *Proc Natl Acad Sci U S A*. 2014;111:9887–92.
3. Curzytek K, Pietowska J, Spiwak R. Drug-induced vitiligo: a meta-analysis of reported cases. *J Physiol Pharmacol*. 2007;58 Suppl 4:66.
4. Harris JE. Chemical-induced vitiligo. *Dermatol Clin*. 2017;35:151–61.
5. Goldstein ME, Tank AW, Fossom LH, Hamil RW. Molecular aspects of the regulation of tyrosine hydroxylase by testosterone. *Brain Res Mol Brain Res*. 1992;14:79–86.

Giovanni Paolino , Pietro Bearzi \*, Santo Raffaele Mercuri 

*Department of Dermatology, IRCCS Ospedale San Raffaele, Milan, Italy*

\* Corresponding author.

*E-mail:* [pietro.bearzi@gmail.com](mailto:pietro.bearzi@gmail.com) (P. Bearzi).

Received 25 November 2019; accepted 3 February 2020

<https://doi.org/10.1016/j.abd.2020.02.010>

0365-0596/ © 2020 Sociedade Brasileira de Dermatologia.

Published by Elsevier España, S.L.U. This is an open access article under the CC BY license (<http://creativecommons.org/licenses/by/4.0/>).

## Malignant melanoma after treatment for Merkel cell carcinoma<sup>☆,☆☆</sup>



*Dear Editor,*

A 98-year-old male was referred complaining of a mass on his left cheek. He had never received immunosuppressive therapy. Physical examination showed a solid, dome-shaped, reddish tumor, 35 mm in diameter, on his left cheek. Microscopic examination of a biopsy specimen revealed an

infiltrative tumor in the dermis. The tumor was composed of sheets and trabeculae of atypical cells with scant cytoplasm, and round nuclei with stippled chromatin (Fig. 1). Immunohistochemistry results revealed that the tumor cells stained positive for cytokeratin 20 and neuron specific enolase. The patient underwent total resection of the tumor. However, because of the patient's advanced age, neither the patient nor his family wished further treatment, including radiotherapy, choosing follow-up visits only. Two years later, he presented again with erosion of the right hallux. Physical examination showed widespread erosion of his right hallux, which in part had a reddish nodule. The nail had completely disappeared (Fig. 2). Histological examination revealed many atypical cells infiltrating irregularly from the epidermis to the dermis (Fig. 3). These atypical cells were immunoreactive for MART-1 and HMB-45. For the same reason as before, the patient and his fam-

<sup>☆</sup> How to cite this article: Ishikawa M, Yamamoto T. Malignant melanoma after treatment for Merkel cell carcinoma. *An Bras Dermatol*. 2020;95:662–4.

<sup>☆☆</sup> Study conducted at the Fukushima Medical University, Fukushima, Japan.