




3. Zanniello R, Pilloni L, Conti B, Faa G, Rongioletti F. Late-onset nevus comedonicus with follicular epidermolytic hyperkeratosis: case report and review of the literature. *Am J Dermatopathol*. 2019;41:453–5.
4. Vora RV, Kota RS, Sheth NK. Dermoscopy of nevus comedonicus. *Indian Dermatol Online*. 2017;8:388–9.
5. Kamińska-Winciorek G, Spiewak R. Dermoscopy on nevus comedonicus: a case report and review of the literature. *Postepy Dermatol Alergol*. 2013;30:252–4.

Cesare Massone ^{a,*}, Sanja Javor ^a, Simona Sola ^{a,b}

^a *Dermatology Unit, Galliera Hospital, Genova, Italy*

^b *Surgical Pathology, Galliera Hospital, Genova, Italy*

* Corresponding author.

E-mail: cesare.massone@gmail.com (C. Massone).

Received 21 December 2019; accepted 4 March 2020

Available online 14 September 2020

<https://doi.org/10.1016/j.abd.2020.03.018>

0365-0596/ © 2020 Sociedade Brasileira de Dermatologia.

Published by Elsevier España, S.L.U. This is an open access article under the CC BY license (<http://creativecommons.org/licenses/by/4.0/>).

Squamous cell carcinoma superimposed on necrobiosis lipoidica: a rare complication^{☆,☆☆}



Dear Editor,

Necrobiosis lipoidica (NL) is a chronic idiopathic disease, of a granulomatous nature, which affects the dermis. The lesions are characterized by brownish-yellow plaques, and the most common location is the pre-tibial region. It more often affects females (3:1) and appears, in general, from the third decade of life onwards. There is an association with diabetes mellitus (DM), and microangiopathy is considered an etiopathogenic factor for the condition. Ulceration is a common complication, while reports of the onset of squamous cell carcinoma (SCC) in NL lesions are rare.^{1,2} After reviewing the literature, 16 cases of SCC in NL lesions were retrieved.^{3–5}

A 62-year-old female patient presented an ulcerated, hyperkeratotic lesion in the NL area, on the right leg, about three months prior, with no history of local trauma. She had been diagnosed with NL in the pre-tibial region of both legs ten years before, with no history of recurrent ulceration. The patient had controlled systemic arterial hypertension and type 2 DM. She used oral hypoglycemic agents, with good control in the last years, and did not present retinopathy or diabetic nephropathy. At the physical examination, the patient presented atrophic bilateral plaques on the pre-tibial region and, on her right leg, a small hyperkeratotic ulcerated plaque over a NL lesion (*fig. 1*). The anatomopathological examination showed a moderately differentiated SCC with invasion of the reticular dermis in an NL lesion (*Figs. 2 and 3*). No palpable lymphadenomegalies were observed. The SCC was excised and the wound was closed with a graft. The patient evolved well in the immediate and late postoperative period. The anatomopathological examination showed tumor-free margins.

NL is a chronic degenerative disease of the dermal connective tissue characterized clinically by yellowish plaques with a narrow granulomatous border, central atrophy, and a tendency to ulceration, most commonly affecting the pre-tibial region of the lower limbs. It is more frequently observed in diabetic patients and, unlike in the reported, most patients also present mic

The etiology and pathogenesis of NL are uncertain; it is believed that external trauma, primary vascular disorders, and microangiopathy can contribute to its development, regardless of the presence of DM.¹

The onset of SCC in areas of ulceration and scarring is well documented in a variety of skin diseases. Ulceration is the main complication of NL, observed in a quarter of patients with this disease. However, despite presenting a chronic course and a tendency to ulceration, the onset of SCC in NL lesions has been seldom reported. It is not clear whether the transformation to SCC is the result of chronic ulceration or of long-standing changes in NL. Risk factors that may be involved in malignant transformation include loss of melanin, which facilitates the lesion, chronic inflammation, and hypoxia.^{2,3} In the present patient, the neoplasm presented as a new ulceration ten years after the diagnosis of the disease, a long period – similarly to other cases described in the literature. However, unlike others, the present case of SCC on an NL lesion did not have a history of recurrent or intractable ulcers.^{3–5}

Metastases have been described in the literature, and may be related to delayed diagnosis (ulcerations are common in NL, delaying the diagnosis of SCC).⁵ In the case reported, diagnosis and treatment were performed early; the patient is currently being followed-up and is without lymph node metastases or the appearance of new lesions. To the best of the authors' knowledge, this is the 17th case reported in the international literature.^{3–5}

The onset of SCC on a NL lesion is very rare. This possibility should be considered in patients with NL with chronic ulcers, as well as in new lesions in patients with NL. Early detection and treatment of SCC associated with NL is of fundamental importance to allow conservative surgical treatment and the best possible clinical outcome. rovascular complications related to DM, such as nephropathy and retinopathy.

[☆] How to cite this article: Souza MEV, Recuero JK, Santos MF, Bonamigo RR. Squamous cell carcinoma superimposed on necrobiosis lipoidica: a rare complication. *An Bras Dermatol*. 2020;95:777–779.

^{☆☆} Study conducted at the Dermatology Department, Santa Casa de Misericórdia de Porto Alegre, Porto Alegre, RS, Brazil.

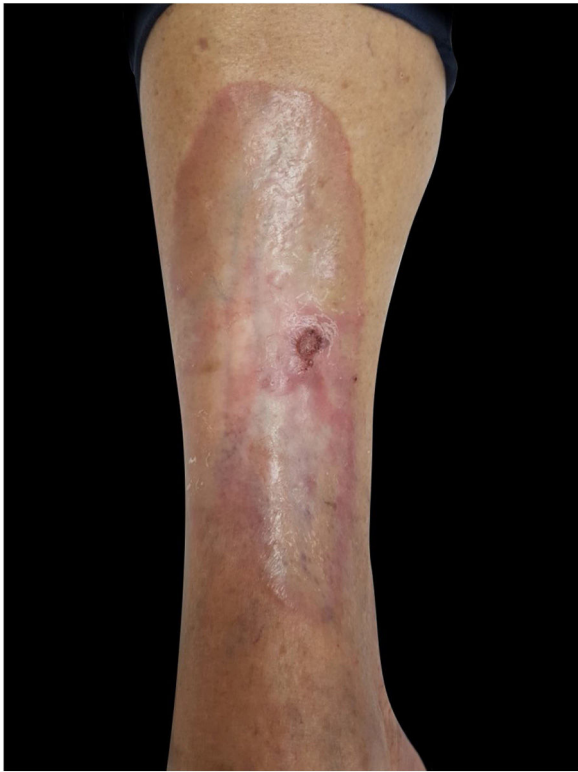

Figure 1 Small hyperkeratotic ulcerated plaque on a necrobiosis lipoidica lesion.

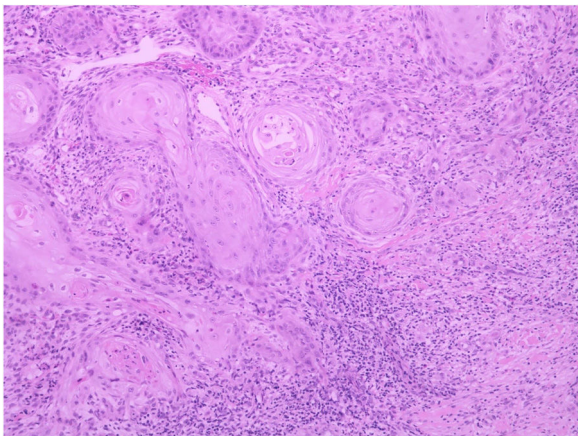


Figure 2 Anatomopathological examination indicating a moderately differentiated squamous cell carcinoma with invasion of the reticular dermis (Hematoxylin & eosin, $\times 20$).

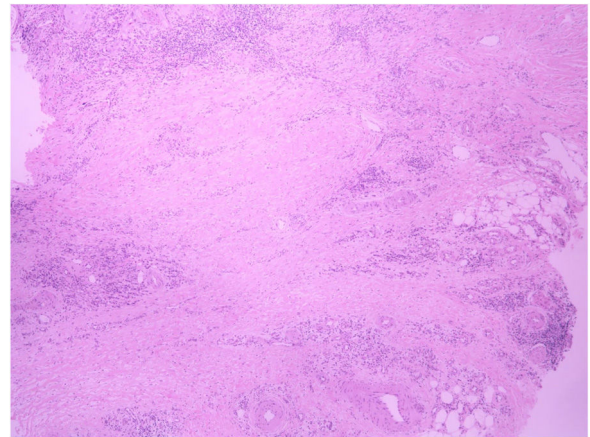


Figure 3 Diffuse areas of collagen degeneration, characteristic of necrobiosis lipoidica (Hematoxylin & eosin, $\times 5$).

Financial support

None declared.

Authors' contributions

Maria Emília Vieira de Souza: Approval of the final version of the manuscript; conception and planning of the study; elaboration and writing of the manuscript; critical review of the literature; critical review of the manuscript.

Julia Kanaan Recuero: Approval of the final version of the manuscript; conception and planning of the study; elaboration and writing of the manuscript; obtaining, analyzing, and interpreting the data; intellectual participation in propaedeutic and/or therapeutic conduct of studied cases; critical review of the literature; critical review of the manuscript.

Manoella Freitas Santos: Approval of the final version of the manuscript; conception and planning of the study; elaboration and writing of the manuscript; critical review of the literature; critical review of the manuscript.





Renan Rangel Bonamigo: Approval of the final version of the manuscript, conception and planning of the study, elaboration and writing of the manuscript; obtaining, analyzing, and interpreting the data; effective participation in research orientation; intellectual participation in propaedeutic and/or therapeutic conduct of studied cases; critical review of the literature; critical review of the manuscript.

Conflicts of interest

None declared.

References

1. Sibbald C, Reid S, Alavi A. Necrobiosis lipoidica. *Dermatol Clin.* 2015;33:343–60.
2. Boateng B, Hiller D, Albrecht H, Hornstein O. Cutaneous micro-circulation in pretibial necrobiosis lipoidica. Comparative laser doppler flowmetry and oxygen partial pressure determinations in patients and healthy probands. *Hautarzt.* 1993;44:581–6.
3. Kolovics J, Mattes LP, Andersen KE, Beck-Nielsen H. Squamous cell carcinoma developing in necrobiosis lipoidica in a diabetic patient. *Ugeskr Laeger.* 2015;177. V01150054.
4. Lefkovits Y, Adler A. Fatal squamous cell carcinoma from necrobiosis lipoidica diabetorum in a diabetic patient. *Endocrinol Diabetes Metab Case Rep.* 2019;2019:19–27.
5. Uva L, Freitas J, Soares de Almeida L, Vasques H, Moura C, Miguel D, et al. Squamous cell carcinoma arising in ulcerated necrobiosis lipoidica diabetorum. *Int Wound J.* 2015;12:741–3.

Maria Emilia Vieira de Souza ^{a,b,*}, Julia Kanaan Recuero ^b, Manoella Freitas Santos ^{a,b}, Renan Rangel Bonamigo ^{a,b}

^a *Department of Dermatology, Santa Casa de Misericórdia de Porto Alegre, Porto Alegre, RS, Brazil*

^b *Universidade Federal de Ciências da Saúde de Porto Alegre, Porto Alegre, Rio Grande do Sul, Brazil*

* Corresponding author.

E-mail: maria.vsouza@hotmail.com (M.E. Souza).

Received 24 November 2019; accepted 5 March 2020

Available online 21 August 2020

<https://doi.org/10.1016/j.abd.2020.03.014>

0365-0596/ © 2020 Sociedade Brasileira de Dermatologia.

Published by Elsevier España, S.L.U. This is an open access article under the CC BY license

(<http://creativecommons.org/licenses/by/4.0/>).

Phthiriasis capitis *ab initio*. Use of entodermoscopy for quick differentiation between *Phthirus pubis* and *Pediculus capitis* nits^{☆,☆☆}



Dear Editor,

Phthiriasis pubis (crab louse infestation) is an ectoparasitosis transmitted mostly by skin to skin contact, primarily located in the genital areas and secondly, if treated late, expanding towards the armpits or other parts of the adult body with thick hair. In children before sexual maturation, the affected sites can include the eyelashes or head hair, usually after contact with an adult who has been sexually infected. Commonly, diagnosis is easy and requires finding eggs (nits) and/or insects, generally firmly hooked to hair shaft base. Because phthiriasis is included in sexually transmitted diseases, it is recommended to expand investigation to other venereal diseases.

Recent reports about *Phthirus pubis* seem to suggest a change of its usual behavior, favoring a primary scalp location without genital involvement, as already described by some authors and observed in a personal unpublished series.^{1–3}

Although fomites can carry parasites anywhere, cases considered in this letter refer to adults or school age children whose infestation was neither transmitted through objects or sexual intercourse, nor by non-sexual touching (i.e., when children sleep with a parent). A careful anamnestic reconstruction was only suggestive for a head-to-head direct contact modality.⁴

This scenario, not yet fully investigated, could be partially explained with some hypotheses. One of the most probable could be related to the very popular practice of pubis and underarm trichotomy or laser epilation of any part of the body that eliminates the parasite's natural habitat. Another suggestive hypothesis could regard some connection between terrestrial climatic changes and different receptivity of human skin to *P. pubis*. Anyway, in such unusual conditions, crabs appear to skip genital targets and going directly towards cephalic areas.

If crab lice develop in specific context such as schools, where physical contacts are very common among children, there is a risk of misdiagnosis because school is the place where *Pediculus capitis* is normally expected as main cause of morbidity and head itch. Unfortunately, scalp itch and nits alone are not sufficient to formulate a correct differentiation with naked eye between *P. capitis* and *P. pubis*; on the contrary, it is possible by entodermoscopy, which is dermatoscopy with an entomological focus. In fact, the nits of these two different species of parasite, although similar at first glance, have two pathognomonic parts that help to distinguish them: the operculum and the fixing sleeve to the hair shaft.⁵ *P. capitis* nits are closed on top by a dome drilled cover (operculum+aeropyles) and glued to hair shaft by a long, thin, tubular sleeve (Fig. 1). *P. pubis* nits instead have a conically shaped operculum and a short, thick sleeve (Fig. 2). These morpho-

[☆] How to cite this article: Scanni G. Phthiriasis capitis *ab initio*. Use of entodermoscopy for quick differentiation between *Phthirus pubis* and *Pediculus capitis* nits. *An Bras Dermatol.* 2020;95:779–781.

^{☆☆} Study conducted at the Service of Medicine, Poliambulatorio Distretto Unico, Azienda Sanitaria Locale Della Provincia di Bari, Bari, Italy.