

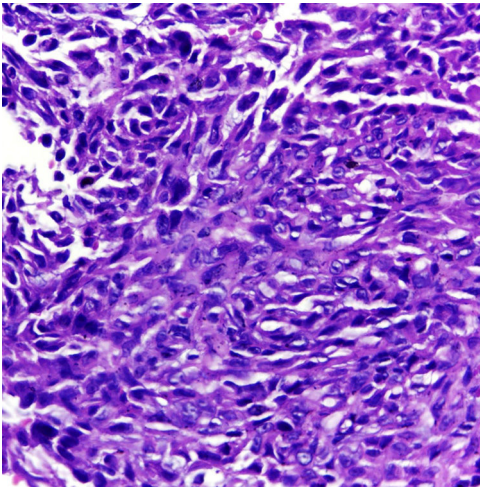Figure 3 Histopathological examination showing an infiltrative neoplasm consisting of epithelioid and spindle cells with eosinophilic cytoplasm and irregular nuclei with evident nucleoli (Hematoxylin & eosin, $\times 400$).

in almost 50% of cases. INI-1 is deficient in approximately 90% of cases.^{1,4} Complete surgical resection is the basis of curative therapy for ES. Some authors strongly recommend radical local excision, with amputation, as the first operative procedure.⁵ The authors report a rare case of upper limb ES, with long evolution before the diagnosis; attention is drawn to the important role of the dermatologist in the clinical recognition of this neoplasm.

Financial support

None declared.

Authors' contributions

Maraya de Jesus Semblano Bittencourt: Approval of the final version of the manuscript; collection, analysis, and interpretation of data; critical review of the literature; critical review of the manuscript.

Caren dos Santos Lima: Drafting and editing of the manuscript; collection, analysis, and interpretation of data; critical review of the literature; critical review of the manuscript.

Aline de Lima Dias: Approval of the final version of the manuscript; Drafting and editing of the manuscript; intellectual participation in propaedeutic and/or therapeutic conduct of studied cases; critical review of the literature; critical review of the manuscript.

Camilla Côrrea Neri: Drafting and editing of the manuscript; collection, analysis, and interpretation of data; critical review of the literature; critical review of the manuscript.

Conflicts of interest

None declared.

References

1. Thway K, Jones RL, Noujaim J, Fisher C. Epithelioid sarcoma: diagnostic features and genetics. *Adv Anat Pathol*. 2016;23:41–9.
2. Nunes LF, Fiod NJJ, Vasconcelos RAT, Meoas W, Rezende JFN. Epithelioid sarcoma: clinical behavior, prognostic factors and survival. *Rev Col Bras Cir*. 2010;37:251–5.
3. Fleury LFF Jr, Sanches JA Jr. Primary cutaneous sarcomas. *An Bras Dermatol*. 2006;81:207–21.
4. Akpınar F, Dervis E, Demirkesen C, Akpınar AC, Ergun SS. Epithelioid sarcoma of the extremities. *Indian J Dermatol Venereol Leprol*. 2014;80:168–70.
5. Burgos AM, Chávez JG, Sánchez JL, Sánchez NP. Epithelioid sarcoma: a diagnostic and surgical challenge. *Dermatol Surg*. 2009;35:687–91.

Maraya de Jesus Semblano Bittencourt ^{ID},
Caren dos Santos Lima ^{ID}, Aline de Lima Dias ^{ID}*,
Camilla Côrrea Neri ^{ID}

Department of Dermatology, Centro Universitário do Estado do Pará, Belém, PA, Brazil

*Corresponding author.

E-mail: dias.alinelima@gmail.com (A.L. Dias).

Received 21 January 2020; accepted 10 June 2020

Available online 19 November 2020

<https://doi.org/10.1016/j.abd.2020.06.007>

0365-0596/ © 2020 Sociedade Brasileira de Dermatologia.

Published by Elsevier España, S.L.U. This is an open access article under the CC BY license (<http://creativecommons.org/licenses/by/4.0/>).

Etanercept-induced palisaded neutrophilic granulomatous dermatitis^{☆,☆☆}



Dear Editor,

A 37-year-old female was referred to this hospital, complaining of fever and induration and swelling of the chest wall. She had rheumatoid arthritis and been treated with

non-steroidal anti-inflammatory drugs and methotrexate for six years, as well as etanercept (25 mg per three weeks) for two years, prior to presentation. Physical examination revealed a reddish induration with tenderness and swelling of the left breast (Fig. 1). It was also accompanied by a number of tiny pustules. Laboratory data showed positive anti-nuclear antibody (1:160), elevated C-reactive protein (14.91 mg/dL), anti-SS-A antibodies (> 240 U/mL), and positive Schirmer's test (left eye; 2 mm). The patient had not been diagnosed as having Sjögren's syndrome until presentation at this hospital. A biopsy specimen showed basophilic degeneration of collagen fibers mixed with numerous nuclear debris in the upper dermis (Fig. 2). There was also mild interface dermatitis. Immunohistochemistry

[☆] How to cite this article: Ishikawa M, Yamamoto T. Etanercept-induced palisaded neutrophilic granulomatous dermatitis. *An Bras Dermatol*. 2021;96:117–9.

^{☆☆} Study conducted at the Department of Dermatology, Fukushima Medical University, Fukushima, Japan.

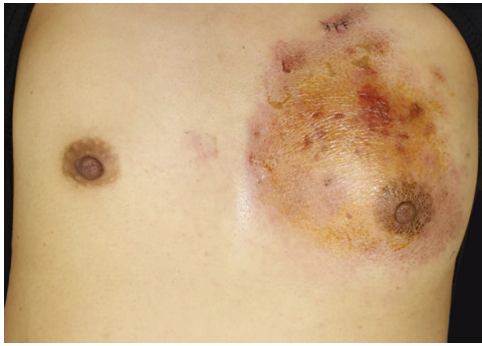


Figure 1 Clinical features of the trunk. A reddish induration with tenderness and swelling on the left breast.

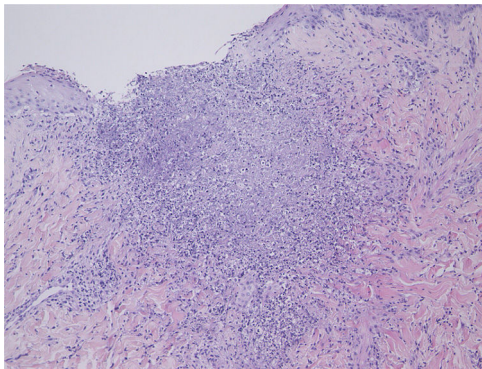


Figure 2 The histopathological specimen showed basophilic degeneration of collagen fiber, mixed with numerous nuclear debris in the upper dermis (Hematoxylin & eosin, $\times 100$).

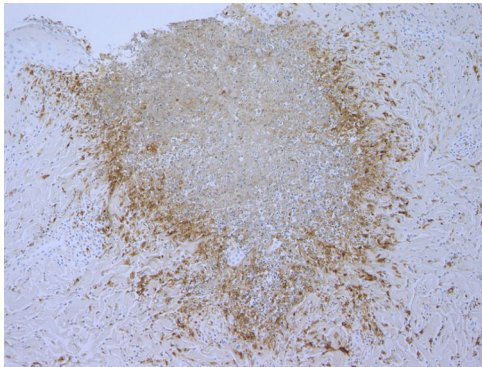


Figure 3 Palisaded histiocytes surrounding degenerated collagen fibers (CD68, $\times 100$).

results revealed a number of CD68-positive palisaded histiocytes surrounding degenerated collagen fibers (Fig. 3). Although the patient was treated with antibiotics for cellulitis initially, these had little effect. Since the patient did not show any other obvious symptoms, several studies were performed in order to identify the source of fever. Examination of cerebrospinal fluid revealed that she had aseptic meningitis, which was considered as a part of the central nervous system involvement in autoimmune disease. The patient's fever and induration improved with 50 mg of prednisolone. After recovery, etanercept therapy was stopped. Although the patient continued treatment with non-steroidal anti-inflammatory drugs and methotrexate,

three months after stopping etanercept, she was free from recurrence.

In the present case, infiltrative erythema occurred in a patient with rheumatoid arthritis and Sjögren's syndrome two years after starting treatment with etanercept, and the eruption has not occurred since the etanercept treatment was stopped. Histopathological examination revealed characteristic findings of palisaded neutrophilic granulomatous dermatitis (PNGD) and interface dermatitis. Considering the clinical course and the histopathological features, PNGD could be induced by etanercept in the present case. PNGD is a pathological concept characterized by an inflammation pattern showing a palisading infiltration of histiocyte surrounding areas of necrobiosis, which occasionally occurs in patients with autoimmune diseases such as rheumatoid arthritis, Sjögren's syndrome, and eosinophilic granulomatosis with polyangiitis.¹ To date, there have only been few reported cases of PNGD occurring after treatment with etanercept, including the present case.²⁻⁴ In contrast to other TNF- α inhibitors, etanercept, a receptor fusion protein, is considered not to strongly suppress TNF- α activity and this may enable TNF- α to form granuloma. Otherwise, etanercept may modulate cytokines other than TNF, which cannot be done by other TNF inhibitors. In addition, etanercept can enhance T-cell production of interferon-gamma, which is a key player in granuloma formation.⁵ By contrast, there are reports that adalimumab and infliximab also induce sarcoid or sarcoid-like granulomas, and thus other mechanisms leading to granuloma induction may exist. Further studies are necessary to clarify the mechanisms of TNF inhibitors-induced granulomatous diseases.

Financial support

None declared.

Authors' contributions

Masato Ishikawa: Design and planning of the study; drafting and editing of the manuscript; collection, analysis, and interpretation of data; critical review of the literature.

Toshiyuki Yamamoto: Approval of the final version of the manuscript; design and planning of the study.



Conflicts of interest

None declared.

References

- Hantash BM, Chiang D, Kohler S, Fiorentino D. Palisaded neutrophilic and granulomatous dermatitis associated with limited systemic sclerosis. *J Am Acad Dermatol.* 2008;58:661-4.
- Nguyen TA, Celano NJ, Matiz C. Palisaded neutrophilic granulomatous dermatitis in a child with juvenile idiopathic arthritis on etanercept. *Pediatr Dermatol.* 2016;33:e156-7.

3. Chou CL, Wang KH, Chiang YY. Palisaded neutrophilic and granulomatous dermatitis associated with the initiation of etanercept in rheumatoid arthritis: a case report. *Dermatol Sin.* 2011;29:129–33.
4. Deng A, Harvey V, Sina B, Strobel D, Badros A, Junkins-Hopkins JM, et al. Interstitial granulomatous dermatitis associated with the use of tumor necrosis factor alpha inhibitors. *Arch Dermatol.* 2006;142:198–202.
5. Daïen CI, Monnier A, Claudepierre P, Constantin A, Eschard JP, Houvenagel E, et al. Sarcoid-like granulomatosis in patients treated with tumor necrosis factor blockers: 10 cases. *Rheumatology (Oxford)*. 2009;48:883–6.

Masato Ishikawa *, Toshiyuki Yamamoto 
Fukushima Medical University, Fukushima, Japan

*Corresponding author.

E-mail: ishimasa@fmu.ac.jp (M. Ishikawa).

Received 18 February 2020; accepted 16 June 2020

Available online 16 November 2020

<https://doi.org/10.1016/j.abd.2020.06.005>

0365-0596/ © 2020 Published by Elsevier España, S.L.U. on behalf of Sociedade Brasileira de Dermatologia. This is an open access article under the CC BY license (<http://creativecommons.org/licenses/by/4.0/>).