

pressed patients (HIV-positive and chronic kidney disease) presented vesicles on an erythematous base; the distribution in one case was dermatomal and in the other the lesions were grouped. These findings are clinically consistent with the Herpesviridae family viruses. In the literature, vesicular lesions similar to varicella are reported, with a more dispersed and diffuse distribution and located on the trunk.^{3,5} Thus, the clinical and evolution characteristics can help to differentiate this particular injury. A polymerase chain reaction test of a sample of the lesion is very useful in the identification of the causative virus.⁴

The prevalence of skin lesions observed in the present study was much lower than that found by Recalcati, but similar to that reported by Tamaro.^{1,3}

The skin manifestations found in this study are similar to those caused by other viruses, and it cannot be concluded that there is a pathognomonic skin lesion of SARS-CoV-2.

As previously reported, no correlation with disease severity was observed.^{1,4} The deficit in the immune system can cause other infections, and the established therapy can also cause skin lesions; therefore, it is essential to carry out detailed studies in each case to make a better differential diagnosis.

Financial support

None declared.

Author contribution

Azucena Hernández Rousselin: Approval of the final version; study conception and planning; writing of the manuscript; data collection, analysis and interpretation.

Conflicts of interest

None declared.

References

1. Recalcati S. Cutaneous manifestations in COVID-19: a first perspective. *J Eur Acad Dermatol Venereol.* 2020;34:e212–3.
2. Criado PR, Abdalla BMZ, de Assis IC, et al. Are the cutaneous manifestations during or due to SARS-CoV-2 infection/COVID-19 frequent or not? Revision of possible pathophysiologic mechanisms. *Inflamm Res.* 2020;2:1–12.
3. Tamaro A, Adebajo GAR, Parisella FR, Pezzuto A, Rello J. Cutaneous manifestations in COVID-19: the experiences of Barcelona and Rome. *J Eur Acad Dermatol Venereol.* 2020;34:e306–7.
4. De Giorgi V, Recalcati S, Jia Z, Chong W, Ding R, Deng Y, et al. Cutaneous manifestations related to coronavirus disease 2019 (COVID-19): A prospective study from China and Italy. *J Am Acad Dermatol.* 2020;83:674–5.
5. Marzano AV, Genovese G, Fabbrocini G, Pigatto P, Monfrecola G, Piraccini BM, et al. Varicella-like exanthem as a specific COVID-19-associated skin manifestation: Multicenter case series of 22 patients. *J Am Acad Dermatol.* 2020;83:280–5.

Azucena Hernández Rousselin *

Department of Internal Medicine, Dermatology Unit, Hospital Roosevelt, Guatemala, Guatemala

* Corresponding author.

E-mail: zcn28hr@gmail.com

Received 14 July 2020; accepted 20 August 2020

Available online 17 November 2020

<https://doi.org/10.1016/j.abd.2020.08.005>

0365-0596/ © 2020 Sociedade Brasileira de Dermatologia.

Published by Elsevier España, S.L.U. This is an open access article under the CC BY license (<http://creativecommons.org/licenses/by/4.0/>).

Prevalence of infection by *Bartonella* spp. in patients with psoriasis^{☆,☆☆}



Dear Editor,

Psoriasis (Ps) is a chronic multisystem inflammatory disease that, in addition to the genetic factor, has other triggers such as emotional stress, nutritional deficit, endocrine problems, and infections. The activation of immune system cells is considered an important factor in the pathogenesis of Ps, and several infectious agents have been related to this activation. To modulate the immune response in patients with

Ps, the systemic treatment of the disease may be based on immunosuppressive drugs, which facilitates the spread of opportunistic infections.¹

Bacteria of the genus *Bartonella* are fastidious Gram-negative coccobacilli distributed worldwide (Fig. 1). Currently, the genus has 45 species and subspecies, of which at least 17 are capable of infecting humans. Most of these bacteria are transmitted by hematophagous arthropods, and some of their reservoirs are domestic animals, mainly dogs and cats. Although they have been neglected, the number of studies on *Bartonella* spp. is increasing, as well as the recognition of their importance. These agents have been linked to a wide spectrum of clinical manifestations, ranging from asymptomatic infection to life-threatening conditions, such as endocarditis.²

There are no diagnostic tests with sufficiently high sensitivity and specificity. In addition, bartonellosis is not included in the diagnostic hypotheses by most physicians, which contributes to the underdiagnosis of these infections.² This study aimed to assess the prevalence of *Bartonella* spp.

☆ How to cite this article: Santos LS, Drummond MR, Magalhães RF, Silva MN, Ferreira PAR, Velho PENF. Prevalence of infection by *Bartonella* spp. in patients with psoriasis. *An Bras Dermatol.* 2021;96:107–10.

☆☆ Study conducted at the Faculty of Medical Sciences, Universidade Estadual de Campinas, Campinas, SP, Brazil.

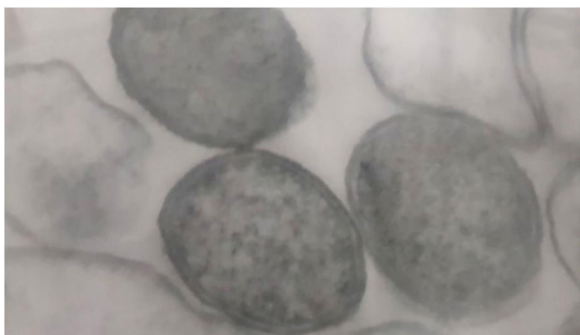


Figure 1 Transmission electronmicroscopy photomicrograph of a colony of *Bartonella henselae* (ATCC 49793) after 45 days of growth on blood-enriched agar: cocoid and electrondense bacteria with a tri-laminar wall, 50,000 \times .

infection through molecular and microbiological tests in Ps patients and a control group of volunteers.

The project was approved by the Institutional Research Council of the Universidade Estadual de Campinas (University of Campinas), under protocol CAEE: 48057415.5.0000.5404.

Blood samples were obtained from 30 Ps patients over 18 years of age, with mild to severe manifestations in different therapeutic regimens who agreed to participate in the study, as well as 30 volunteers – Unicamp students or employees over 18 years of age who denied clinical symptoms, were not pregnant, and agreed to participate in the study.

The samples were processed as summarized in Fig. 2. Liquid enrichment cultures and solid cultures were performed as previously described.³ From whole blood and culture samples, DNA was extracted using the QIAmp DNA Mini Kit (Qiagen®).

From the obtained DNA, genus-specific conventional PCRs (*ITS* region) and *Bartonella henselae*-specific PCRs were performed: double amplified PCR (nested) for the *ftsZ* region and real-time PCR for the *gltA* region. The quality of the extracted DNA and the absence of amplification inhibitors were tested using conventional PCR for the *GAPDH* gene.

B. henselae DNA was detected in 20% (6/30) of Ps patients and in 10% (3/30) of healthy volunteers who denied symptoms at the time of blood sample collection (Table 1). Using Fisher's exact test, no statistical difference was observed between the two groups ($p=0.23$).

Ps is a multifactorial, inflammatory, and immune-mediated disease. Although there is no consensus on the exact mechanisms of action in its pathogenesis, there is strong evidence that external factors, such as super antigens, have a great capacity to stimulate the inflammatory response of the disease.¹ Microorganisms have been associated with Ps (including β -hemolytic streptococci, *Staphylococcus aureus*, *Porphyromonas gingivalis*, *Candida albicans*, *Chlamydia psittaci*, human immunodeficiency virus, and hepatitis C virus), but there is limited evidence that antimicrobial therapy has any direct benefit in crisis prevention. Ps is independently associated with a higher risk of serious infections, which is increased by the use of immunomodulatory treatments.¹

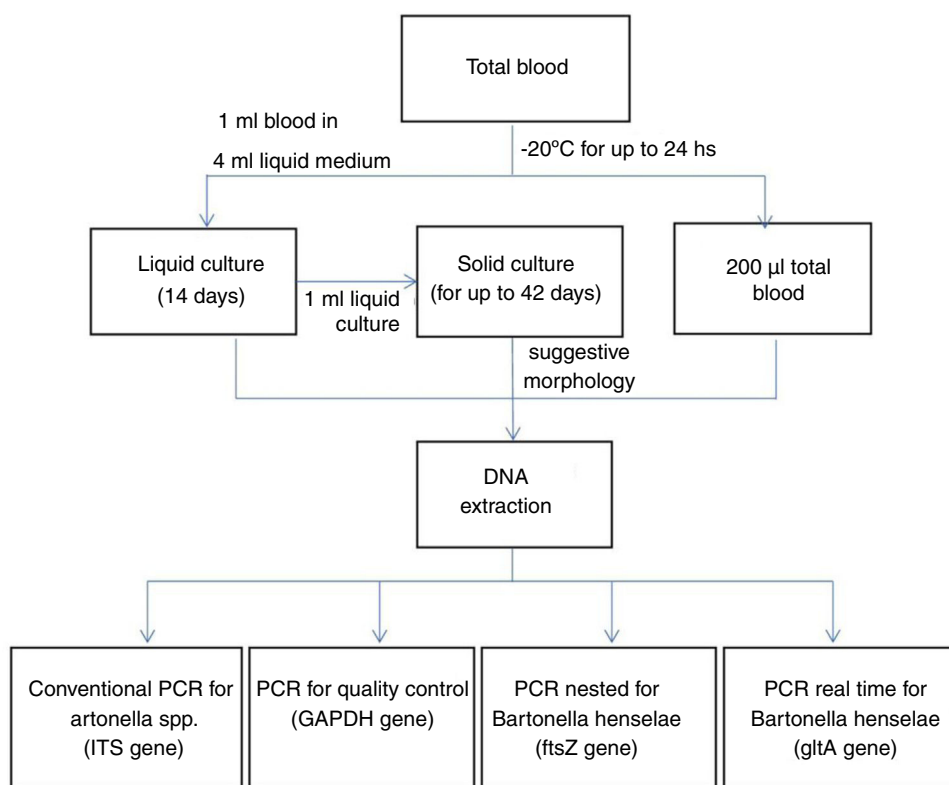


Figure 2 Flowchart of the procedures performed.

Table 1 Results of positive samples.

Positives	Conventional PCR liquid culture	Nested PCR whole blood	Nested PCR liquid culture	PCR whole blood	Real-time PCR liquid culture	Real-time PCR solid culture
PS5	-	-	-	+	-	-
PS16	-	-	+	-	-	-
PS18	-	-	-	+	-	-
PS20	-	-	+	+	+	-
PS28	-	-	-	-	-	+
PS30	-	-	+	-	-	-
CG13	+	+	-	-	-	-
CG36	-	+	-	-	-	-
CG40	-	+	-	-	-	-

PS, patients; CG, control group.

Infection by *Bartonella* spp. was documented in 3.2% of 500 blood donors using a single conventional genus-specific PCR, from samples of liquid and solid culture.⁴

Bartonella spp. was detected in patients with Ps and psoriatic arthritis (PsA). One patient with Ps presented with cat-scratch disease during treatment with adalimumab, and another patient with PsA presented mesenteric lymphadenopathy and splenic abscesses. Symptomatic infection by *Bartonella* spp. was detected in other patients who were receiving treatment with immunobiologicals.⁵

One in five patients with Ps and one in ten healthy volunteers presented infection by *B. henselae*. Despite the lack of statistical difference when compared with the control group, this information is important when considering the high prevalence of infection in patients with Ps and even in the control group. Attention is needed for any patient who requires immunobiological treatment or other immunosuppressive drugs and who presents with possible expressions of infection by *Bartonella* spp., such as fever of undetermined origin, cryptogenic hepatitis, lymph node enlargement, endocarditis, sepsis, and granulomatous or angioproliferative reactions. Further studies are needed to assess whether infection by *Bartonella* spp. may worsen Ps expression and the risks of this infection associated with immunosuppressive treatments.

Financial support

CNPq doctoral scholarship 170501/2018-3 (Santos, LS); Fapesp Postdoctoral scholarship 2018/12565-6 (Drummond, MR); CNPq productivity grant 301900/2015-9 (Velho, PENF) and Fundo de Apoio à Dermatologia (Funaderm)/Sociedade Brasileira de Dermatologia.

Authors' contributions

Luciene Silva dos Santos: Approval of the final version of the manuscript; design and planning of the study; drafting and editing of the manuscript; collection, analysis, and interpretation of data.

Marina Rovani Drummond: Approval of the final version of the manuscript; design and planning of the study; drafting and editing of the manuscript; collection, analysis, and interpretation of data; effective participation in research orientation; critical review of the literature; critical review of the manuscript.

Renata Ferreira Magalhães: Approval of the final version of the manuscript; collection, analysis, and interpretation of data.

Marilene Neves da Silva: Collection, analysis, and interpretation of data.

Patricia Andreia Rodrigues Ferreira: Design and planning of the study.







Paulo Eduardo Neves Ferreira Velho: Statistical analysis; approval of the final version of the manuscript; design and planning of the study; elaboration and writing of the manuscript; obtaining, analyzing, and interpreting the data; effective participation in research orientation; intellectual participation in propaedeutic and/or therapeutic conduct of studied cases; critical review of the literature; critical review of the manuscript.

Conflicts of interest

None declared.

References

- Rademaker M, Agnew K, Anagnostou N, Andrews M, Armour K, Baker C, et al. Psoriasis and infection. A clinical practice narrative. *Australas J Dermatol.* 2019;60:91–8.
- Lins KA, Drummond MR, PENF Velho. Cutaneous manifestations of bartonellosis. *An Bras Dermatol.* 2019;94:594–602.
- Drummond MR, Lania BG, de Paiva Diniz PPV, Gilioli R, Demolin DMR, Scorpio DG, et al. Improvement of *Bartonella henselae* DNA detection in cat blood samples by combining molecular and culture methods. *J Clin Microbiol.* 2018;56:e01732–17.
- Pitassi LH, de Paiva Diniz PP, Scorpio DG, Drummond MR, Lania BG, Barjas-Castro ML, et al. *Bartonella* spp. bacteremia in blood donors from Campinas, Brazil. *PLoS Negl Trop Dis.* 2015;9:e0003467.
- Orden AO, Nardi NN, Vilaseca AB, Colombini AC, Barrios NG, Vijnovich Barón A. Cat scratch disease during etanercept therapy in a rheumatoid arthritis patient. *Reumatol Clin.* 2018;14:303–6.

Luciene Silva dos Santos ^a,
Marina Rovani Drummond ^a,
Renata Ferreira Magalhães ^b,
Marilene Neves da Silva ^a,
Patricia Andreia Rodrigues Ferreira ^b,
Paulo Eduardo Neves Ferreira Velho ^{b,*}

^a *Laboratory of Applied Research in Dermatology and Bartonella Infection, Faculty of Medicine, Universidade Estadual de Campinas, Campinas, SP, Brazil*

^b *Dermatology Division, Department of Clinical Medicine, Faculty of Medical Sciences, Universidade Estadual de Campinas, Campinas, SP, Brazil*

* Corresponding author.

E-mail: pvelho@unicamp.br (P.E. Ferreira Velho).

Received 29 January 2020; accepted 14 July 2020

Available online 20 November 2020

<https://doi.org/10.1016/j.abd.2020.07.004>

0365-0596/ © 2020 Sociedade Brasileira de Dermatologia.

Published by Elsevier España, S.L.U. This is an open access article under the CC BY license (<http://creativecommons.org/licenses/by/4.0/>).