

Incapacitating solar urticaria: successful treatment with omalizumab*

Katarina Kieselova¹, Felicidade Santiago¹, Martinha Henrique¹

DOI: <http://dx.doi.org/10.1590/abd1806-4841.20198109>

Abstract: Solar urticaria is a rare form of physical urticaria mediated by immunoglobulin E. The lesions appear immediately after the sun exposure, interfering with the patient's normal daily life. Omalizumab, a monoclonal anti-IgE antibody, has been recently approved for the treatment of chronic spontaneous urticaria, and the latest reports support its role also in the treatment of solar urticaria. Hereby, we report a case of solar urticaria refractory to conventional treatment strategies, with an excellent response to treatment with omalizumab and phototesting normalization.

Keywords: Immunoglobulin E; Light; Photosensitivity disorders; Urticaria

INTRODUCTION

Solar urticaria (SU) is a rare photodermatosis characterized by rapid induction of symptoms and onset of skin lesions after exposure to sunlight. The pathogenesis of the disease has yet not been fully elucidated. Currently, the onset of symptoms is considered to be triggered by a yet to be identified chromophore, which is activated by light of a particular wavelength.¹ The diagnostic process is based on the characteristic clinical history, completed by phototesting to determine the specific wavelength, the triggering spectrum of the light, responsible for the symptoms. Visible light and UVA rays are the most frequently involved.² Solar urticaria has a significant impact on the quality of life of patients, therefore requiring an effective therapy. However, the treatment is challenging and the combination of several therapeutic modalities is almost always necessary.^{1,3} Recently, some cases of SU with successful treatment with omalizumab have been published.⁴

CASE REPORT

The authors report a case of a 60-year-old man with a medical history of familial hypercholesterolemia and solitary kidney. His medication included trazodone, rosuvastatin and fenofibrate. The patient presented to the dermatology department with a 2-year history of an itchy skin eruption. The lesions consisted of short-lasting erythematous patches and wheals, with onset within 5 to 10 minutes after exposure to direct sunlight, appearing initially on the sun-exposed areas, and later on covered ones (Figure 1). The lesions occurred daily, immediately after exposure to daylight, leading to a significant decrease in the quality of life. The patient experienced lipothymia and generalized erythema after short sun exposure on the beach, resulting in an urgent visit to the emergency department and a consequent complete daylight avoidance. Laboratory studies were normal and to evaluate the involved spectrum of light triggering the lesions, phototesting was performed in the phototherapy

Received 21 January 2018.

Accepted 20 May 2018.

* Work conducted at the Department of Dermatology, Centro Hospitalar de Leiria, Leiria, Portugal.

Financial support: None.

Conflict of interest: None.

¹ Dermatology Department, Centro Hospitalar de Leiria, Leiria, Portugal.

MAILING ADDRESS:

Katarina Kieselova

E-mail: katarinakieselova@gmail.com

©2019 by Anais Brasileiros de Dermatologia



room. Exposure to the light from the projector showed reaction after 10 minutes, just as the exposure to UVA light (Waldmann[®] 7001K), with positive reaction with 2J/cm² (Figures 2 and 3). UVB phototesting was negative (Figure 4). Phototesting confirmed the diagnosis of SU to visible light and to UVA.

In this patient, besides the adoption of photoprotection measures, diverse conventional therapies for SU were tried: H1 second generation antihistamines, hydroxychloroquine, azathioprine and low-dose prednisolone. However, the response was poor or incomplete and the patient maintained symptoms. Phototherapy was not performed due to logistic issues. Hypolipidemic drugs were suspended during two months, with no improvement. Omalizumab was commenced at the dose of 300mg s.c. and administered at monthly intervals. The patient achieved clinical remission during the first month of treatment and is still asymptomatic. After 6 months of treatment, we repeated phototesting, which turned out to be negative. No adverse reaction was registered during 16 months of treatment.

DISCUSSION

Solar urticaria belongs to the group of chronic inducible urticarias, with a severe impact in the patient’s daily life. As the presented case shows, there might be a risk of generalized reactions with anaphylaxis upon exposure of large body surface area. The disease course is chronic, with only few cases of complete resolution.⁵ With all this in mind, it is crucial to achieve the control of the disease. The treatment of SU can be very challenging. Sun protective measures to minimize the exposure should be adopted by all patients. The conventional treatment usually leads only to a modest clinical improvement and consists of high dose of second generation H1 antihistamines in monotherapy or in combination with immunosuppressive drugs, phototherapy or photochemotherapy for desensitization, plasmapheresis and intravenous immunoglobulin.^{1,3} In the presented case, several therapeutic options were combined, still with insufficient control of urticaria.

Taking into account the well-known efficacy of omalizumab in the treatment of chronic spontaneous urticaria (CSU), there have

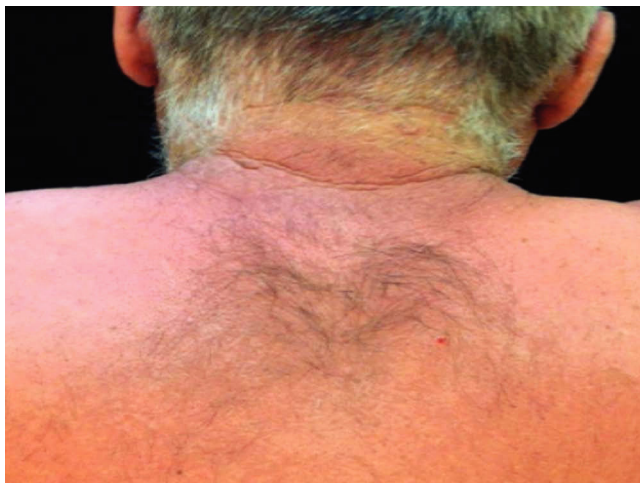

FIGURE 1: Generalized erythema after 5 minutes of sunlight exposure



FIGURE 3: Visible light phototesting revealed an urticarial erythematous plaque after 10 minutes of exposure

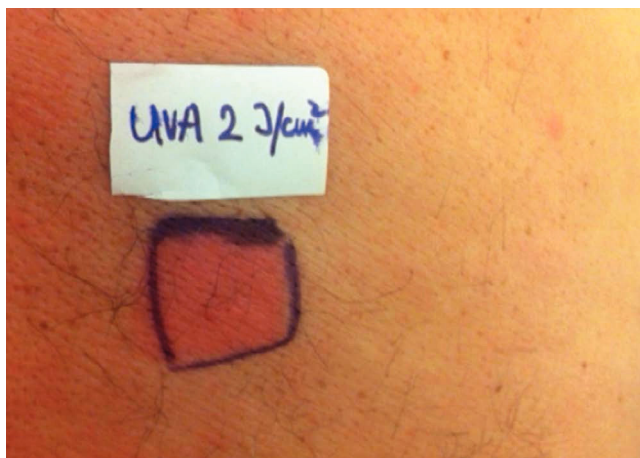

FIGURE 2: Positive UVA phototesting at 2J/cm²

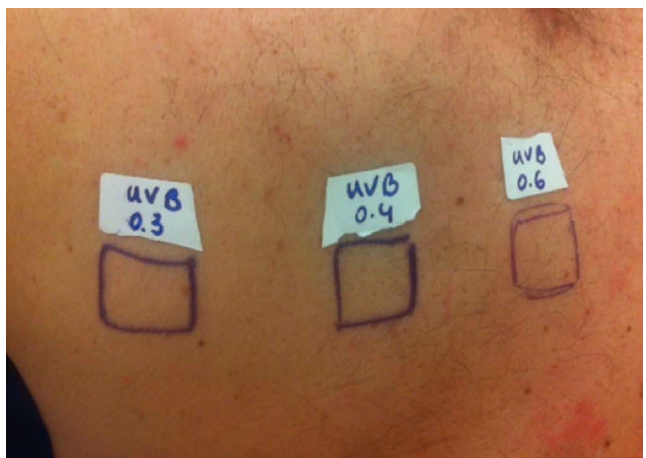


FIGURE 4: Negative UVB phototesting

been several cases recently reported of its efficacy also in patients with SU. To date, 20 articles have been published, the majority being case reports or small case series and one multicentric prospective study in France.⁶⁻⁸

Forty-five cases of SU treated with omalizumab (including the patient presented in this case report) were identified. In 36 patients (80%), the symptoms were controlled successfully. In 9 cases


(20%), the treatment response was partial or insufficient. The treatment schemes differ from patient to patient, with maintenance dosage 150-450 mg every 2 weeks or monthly.⁴ In the presented case, we adopted the dosing as indicated for CSU, with an excellent response. Further studies are warranted to establish the correct therapeutic scheme, but certainly omalizumab will remain a valid and useful option, due to its efficacy and safety profile presented so far. □

REFERENCES

1. Botto NC, Warshaw EM. Solar urticaria. *J Am Acad Dermatol.* 2008;59:909-20.
2. Goetze S, Elsner P. Solar urticaria. *J Dtsch Dermatol Ges.* 2015;13:1250-3.
3. Aubin F, Porcher R, Jeanmougin M, Leonard F, Bedane C, Moreau A, et al. Severe and refractory solar urticaria treated with intravenous immunoglobulins: a phase II multicenter study. *J Am Acad Dermatol.* 2014;71:948-53.e1.
4. Maurer M, Metz M, Brehler R, Hillen U, Jakob T, Mahler V, et al. Omalizumab treatment in patients with chronic inducible urticaria: A systematic review of published evidence. *J Allergy Clin Immunol.* 2018;141:638-49.
5. Beattie PE, Dawe RS, Ibbotson SH, Ferguson J. Characteristics and prognosis of idiopathic solar urticaria: a cohort of 87 cases. *Arch Dermatol.* 2003;139:1149-54.
6. Aubin F, Avenel-Audran M, Jeanmougin M, Adamski H, Peyron JL, Marguery MC, et al. Omalizumab in patients with severe and refractory solar urticaria: A phase II multicentric study. *J Am Acad Dermatol.* 2016;74:574-5.
7. Morgado-Carrasco D, Fustà-Novell X, Podlipnik S, Combalia A, Aguilera P. Clinical and photobiological response in eight patients with solar urticarial under treatment with omalizumab, and review of the literature. *Photodermatol Photoimmunol Photomed.* 2018;34:194-9.
8. Rodríguez-Jiménez P, Chicharro P, Pérez-Plaza A, de Argila D. Response to Omalizumab in Solar Urticaria: Report of 3 Cases. *Actas Dermosifiliogr.* 2017;108:e53-5.


AUTHORS' CONTRIBUTIONS

Katarina Kieselova

 ORCID 0000-0002-0064-7571


Approval of the final version of the manuscript, Conception and planning of the study, Elaboration and writing of the manuscript, Obtaining, analyzing and interpreting the data, Effective participation in research orientation, Intellectual participation in propaedeutic and/or therapeutic conduct of the cases studied, Critical review of the literature, Critical review of the manuscript

Felicidade Santiago

 ORCID 0000-0003-2402-4229

Approval of the final version of the manuscript, Elaboration and writing of the manuscript, Effective participation in research orientation, Intellectual participation in propaedeutic and/or therapeutic conduct of the cases studied

Martinha Henrique

 ORCID 0000-0001-7506-4971

Intellectual participation in propaedeutic and/or therapeutic conduct of the cases studied, Critical review of the literature, Critical review of the manuscript

How to cite this article: Kieselova K, Santiago F, Henrique M. Incapacitating solar urticaria: successful treatment with omalizumab. *An Bras Dermatol.* 2019;94(3):331-3