

## American tegumentary leishmaniasis: severe side effects of pentavalent antimonial in a patient with chronic renal failure\*

Silvio Alencar Marques<sup>1</sup>, Maira Renata Merlotto<sup>1</sup>, Paulo Müller Ramos<sup>1</sup>, Mariangela Esther Alencar Marques<sup>2</sup>

DOI: <http://dx.doi.org/10.1590/abd1806-4841.20198388>

**Abstract:** Pentavalent antimonials are the first-line drug treatment for American tegumentary leishmaniasis. We report on a patient with chronic renal failure on hemodialysis who presented with cutaneous lesions of leishmaniasis for four months. The patient was treated with intravenous meglumine under strict nephrological surveillance, but cardiotoxicity, acute pancreatitis, pancytopenia, and cardiogenic shock developed rapidly. Deficient renal clearance of meglumine antimoniate can result in severe toxicity, as observed in this case. These side effects are related to cumulative plasma levels of the drug. Therefore, second-line drugs like amphotericin B are a better choice for patients on dialysis.

**Keywords:** Amphotericin B; Kidney failure, chronic; Leishmaniasis; Leishmaniasis, cutaneous; Meglumine; Pancreatitis; Renal insufficiency, chronic; Skin ulcer

American tegumentary leishmaniasis (ATL) is an endemic parasitic disease that in Brazil is caused mostly by *Leishmania (Viannia) braziliensis*.<sup>1</sup> Pentavalent antimonials are the first-line drug treatment for ATL.<sup>2,3</sup> Musculoskeletal pain, headache, nausea, and asthenia are reported as common side effects, and cardiotoxicity, hepatotoxicity, nephrotoxicity, and pancreatitis as rare, and associated with cumulative doses.<sup>4,7</sup> The authors report severe side effects associated with the use of meglumine antimoniate (Glucantime®) in a patient presenting chronic renal failure (CRF) due to systemic hypertension, on hemodialysis for two years.

A 42-year-old male patient from São Paulo State, Brazil, complained of rapidly growing cutaneous lesions on the face for four months. Upon examination we observed an ulcerated and verrucous lesion measuring 10.0 cm on the left malar-zygomatic region associated with similar lesions on the lower lip and right infra-au-

ricular area. (Figures 1 and 2). Clinical examination was unremarkable. With the hypothesis of paracoccidioidomycosis or leishmaniasis, the patient underwent a biopsy, and the anatomopathological exam showed chronic inflammatory infiltrate with lymphocytes, plasma cells, and epithelioid granulomas. Amastigotes were seen in the cytoplasm of macrophages, confirming leishmaniasis (Figures 3 and 4). Montenegro skin test was positive, measuring 15 x 15mm. Pre-treatment laboratory workup revealed anemia and confirmed the patient's renal failure. Other exams were normal or negative including HIV serology. Following the nephrological evaluation, we initiated Glucantime® 13.5mg/Sb<sup>v</sup>/kg/IV/daily with the patient hospitalized and under monitored management and routine hemodialysis sessions. On treatment day 5, the patient presented transient supraventricular arrhythmia during Glucantime® administration, which was interrupted. On the same day, the patient developed

Received 22 April 2018.

Accepted 9 August 2018.

\* Work conducted at the Department of Dermatology and Radiotherapy, Faculdade de Medicina de Botucatu, Universidade Estadual Paulista, Botucatu (SP), Brazil.

Financial support: None.

Conflict of interest: None.

<sup>1</sup> Department of Dermatology, Faculdade de Medicina de Botucatu, Universidade Estadual Paulista, Botucatu (SP), Brazil.

<sup>2</sup> Department of Pathology, Faculdade de Medicina de Botucatu, Universidade Estadual Paulista, Botucatu (SP), Brazil.

MAILING ADDRESS:

Silvio Alencar Marques

E-mail: [silvio.marques@unesp.br](mailto:silvio.marques@unesp.br)

©2019 by Anais Brasileiros de Dermatologia



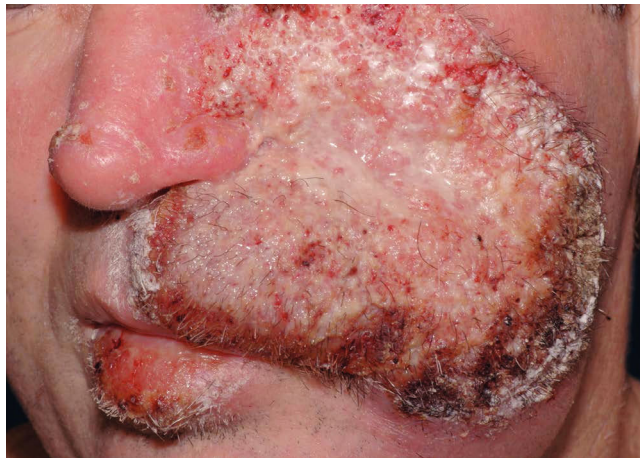

FIGURE 1: Leishmaniasis: ulcerated and verrucous lesion on the left malar-zygomatic region. Ulcerated and infiltrated lesion on the lower-lip

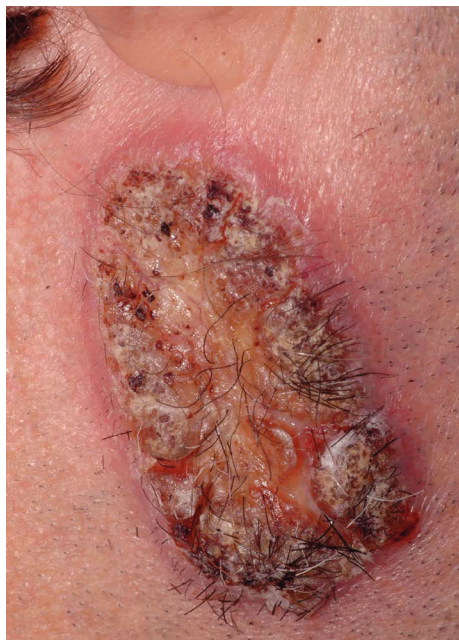

FIGURE 2: Leishmaniasis: ulcerated lesion, partially covered by crusts with infiltrated edges on the right infra-auricular area.

signs and symptoms of severe acute pancreatitis (Ranson 3), rising liver enzymes, pancytopenia (hemoglobin = 6.9 g/dl; white blood cells = 2600/mm<sup>3</sup>; platelets = 52000/mm<sup>3</sup>), and shock. Transferred to the ICU, the patient quickly recovered from shock under volume replacement and vasoactive drugs, but symptomatic improvement of pancreatitis was slow. Although the antimonial treatment was discontinued, surprisingly the cutaneous lesions nearly vanished in a short period of time. With clinical improvement and a residual lesion, we started amphotericin B deoxycholate 0.5mg/kg/daily on hospital day (HD) 28, in maintenance hemodialysis and support treatment. The patient was discharged on HD 50 in good health and

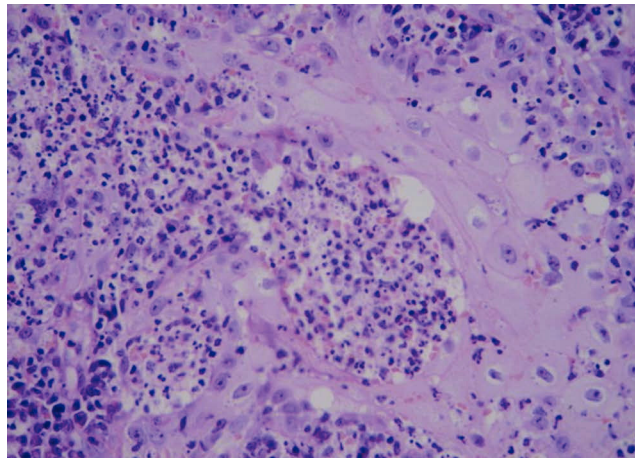


FIGURE 3: Leishmaniasis: pseudo-hyperplasia of the epidermis plus chronic inflammatory infiltrate with lymphocytes, plasma cells, and epithelioid granulomas. (hematoxylin & eosin x400)

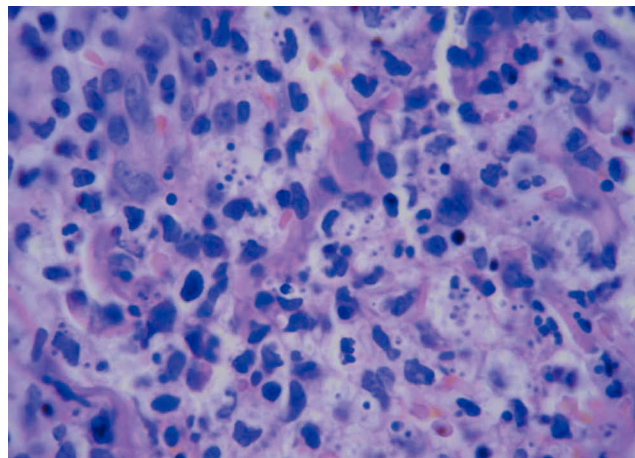


FIGURE 4: Leishmaniasis: close-up showing amastigotes in the cytoplasm of macrophages. (Hematoxylin & eosin x1000/oil)





complete resolution of lesions. One year later he was submitted to renal transplantation and is currently in good clinical condition.

Glucantime® is excreted 80% through the kidneys as active drug.<sup>8</sup> Therefore, there are strict limits for its use in patients presenting reduced renal clearance.<sup>9</sup> Management of this clinical case was initially based on the assumption that hemodialysis would be capable of filtering the antimonial, which did not occur or only occurred partially, resulting in drug accumulation up to 4050 mg/Sb<sup>v</sup> (810mg/Sb<sup>v</sup>/day). Consequently, side effects appeared quickly and were severe, particularly cardiotoxicity and pancreatitis. When a patient presents with definitive and total renal failure, the suggestion is to prescribe amphotericin B deoxycholate, which is eliminated mainly by metabolism and is a dialyzable drug, with the liposomal formulation as an alternative.<sup>10</sup> A beneficial effect of the high plasma antimonial level was the fast and almost complete resolution of the leishmaniasis cutaneous lesions. □

## REFERENCES

- Anversa L, Tiburcio MGS, Richini-Pereira VB, Ramirez LE. Human leishmaniasis in Brazil: a general review. *Rev Assoc Med Bras* (1992). 2018;64:281-9.
- Almeida OL, Santos JB. Advances in the treatment of cutaneous leishmaniasis in the New World in the last ten years: a systematic literature review *An Bras Dermatol*. 2011;86:497-506.
- Revez L, Maia-Elkhoury AN, Nicholls RS, Romero GA, Yadon ZE. Intervention for American cutaneous and mucocutaneous leishmaniasis: A systematic review update. *PLoS One*. 2013;8:e61843.
- Oliveira LF, Schubach AO, Martins MM, Passos SL, Oliveira RV, Marzochi MC, et al. Systematic review of the adverse effects of cutaneous leishmaniasis treatment in the New World. *Acta Trop*. 2011;118:87-96.
- Clementi A, Battaglia G, Floris M, Castellino P, Ronco C, Cruz DN. Renal involvement in leishmaniasis: a review of the literature. *NDT Plus*. 2011;4:147-52.
- Lyra MR, Passos SR, Pimentel MI, Bedoya-Pacheco SJ, Valete-Rosalino CM, Vasconcelos EC, et al. Pancreatic toxicity as an adverse effect induced by meglumine antimoniate therapy in a clinical trial for cutaneous leishmaniasis. *Rev Inst Med Trop Sao Paulo*. 2016;58:68.
- El Jeri HK, Harzallah A, Barbouch S, Bacha MM, Kheder R, Turki S, et al. Visceral leishmaniasis in adults with nephropathy. *Saudi J Kidney Dis Transpl*. 2017;28:95-101.
- Portal.anvisa.gov.br [Internet]. Agência Nacional de Vigilância Sanitária (ANVISA). Glucantime® (antimoniato de meglumine). [cited 2018 Apr 6]. Available from: [http://portal.anvisa.gov.br/datavisa/fila\\_bula/frmVisualizarBula.asp?pNuTransacao=991282015&pIdAnexo=2435258](http://portal.anvisa.gov.br/datavisa/fila_bula/frmVisualizarBula.asp?pNuTransacao=991282015&pIdAnexo=2435258)
- Fontenele e Silva JS, Galvao TF, Pereira MG, Silva MT. Treatment of American tegumentary leishmaniasis in special population: a summary of evidence. *Rev Soc Bras Med Trop*. 2013;46:669-77.
- Bellmann R, Smuszkiewicz P. Pharmacokinetics of antifungal drugs: practical implications for optimized treatment of patients. *Infection*. 2017;45:737-9.

## AUTHORS' CONTRIBUTIONS

Sílvio Alencar Marques	 ORCID	0000-0002-5512-4700
Approval of the final version of the manuscript; Conception and planning of the study; Elaboration and writing of the manuscript		
Maira Renata Merlotto	 ORCID	0000-0002-8918-5640
Obtaining, analyzing, and interpreting the data; Critical review of the literature		
Paulo Müller Ramos	 ORCID	0000-0002-1561-414X
Approval of the final version of the manuscript; Obtaining, analyzing, and interpreting the data		
Mariangela Esther Alencar Marques	 ORCID	0000-0001-6947-5627
Approval of the final version of the manuscript; Obtaining, analyzing, and interpreting the data		

**How to cite this article:** Marques SA, Merlotto MR, Ramos PM, Marques MEA. American tegumentary leishmaniasis: severe side effects of pentavalent antimonial in a patient with chronic renal failure. *An Bras Dermatol*. 2019;94(3):355-7.