

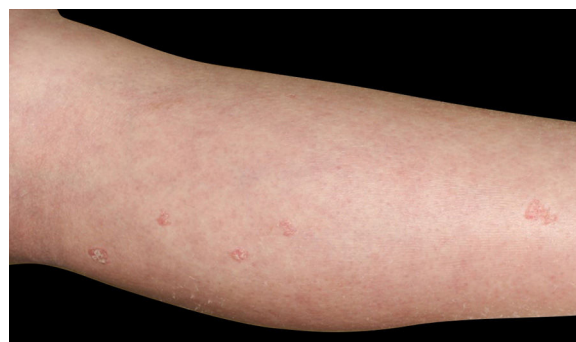## Eruptive superficial porokeratosis in a patient with nephrotic syndrome<sup>☆</sup>



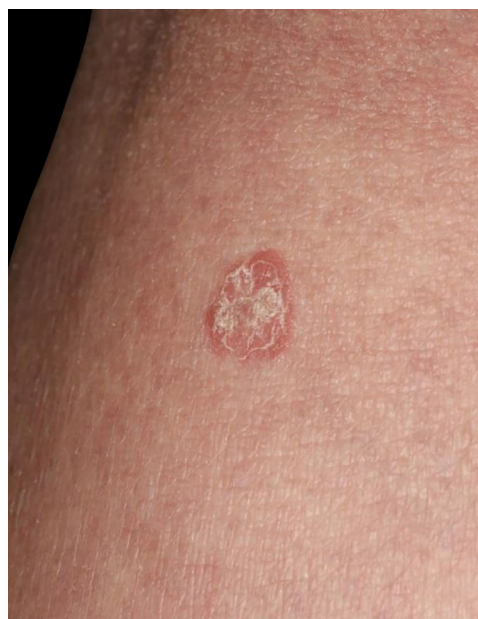Dear Editor,

A 34-year-old female was referred to our department, complaining of multiple asymptomatic lesions that appeared two weeks previously. Physical examination revealed multiple well-circumscribed rounds of flat brownish plaques with slightly elevated borders, some of which were covered by scales (Figs. 1 and 2). The number of lesions was nine in total: six lesions on the right lower leg, and a solitary lesion on the left lower leg, left thigh and right upper extremity. Skin biopsy specimens showed dyskeratotic cells in the thinned epidermis with cornoid lamella, and the absence of a granular cell layer. Superficial perivascular lymphocytic infiltrate in the dermis was also observed (Fig. 3). The lupus band test was negative, and immunostaining for human papillomavirus was also negative. The patient was hospitalized to the Department of Nephrology and Hypertension in our university hospital for nephrotic syndrome and treated with oral prednisolone (25 mg/day), cyclosporine (50 mg/day), and mizoribine (150 mg/day). The patient did not have steroid-induced diabetes. Laboratory data showed abnormal levels of triglyceride (701 mg/dL), total cholesterol (607 mg/dL) and low-density lipoprotein cholesterol (405 mg/dL). Serum immunoglobulin (Ig) G, complements, antinuclear antibodies, anti-DNA antibodies, anti-Sm antibodies, and rheumatoid factor were all within normal ranges. Although the kidney function was normal, proteinuria with hyaline casts was observed, and immunofluorescence examination of renal biopsy revealed granular deposition of IgM and IgG on the basement membrane. Because deposition of complement component 1q was additionally detected, she was initially suspected of lupus nephritis; however, she lacked other symptoms compatible with systemic lupus erythematosus. Topical corticosteroid ointment was applied, but she discontinued the topical therapy.

Eruptive porokeratosis is characterized by rapid onset of porokeratosis, which occasionally presents with more than 100 lesions involving multiple regions, in association with paraneoplastic, immunosuppressive, inflammatory, and other conditions.<sup>1</sup> It is known that porokeratosis develops in association with systemic immunosuppression or under immunosuppressant therapies; however, it is still unclear as to how immunosuppression is associated with the development of porokeratosis.<sup>2</sup> One possible mechanism is that immunosuppression induces an epidermal keratinocyte population either directly or indirectly.<sup>2</sup> The abnormal clone of keratinocytes proliferates in a disorderly manner and disturbs the normal growth of the epidermis.<sup>3</sup> Patients with renal failure rarely develop multiple porokeratosis.<sup>4,5</sup> Since renal dysfunction can induce various immune regulatory alterations, these cases are suggested to be a new subtype of porokeratosis related to immunosuppression.<sup>5</sup> In the



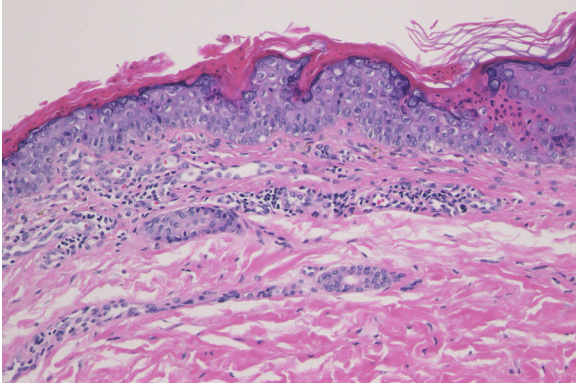
**Figure 1** Physical examination revealed multiple reddish keratotic lesions on the right lower extremity.



**Figure 2** Close-up view showed well-circumscribed, slightly elevated reddish macule with scales.

present case, the patient was initially diagnosed with lupus nephritis. She may develop systemic lupus erythematosus in the future; however, the criteria of lupus nephritis have not been fulfilled as of this moment. In any case, the patient had active nephritis with nephrotic syndrome and was treated with immunosuppressive therapies. The development of porokeratosis was therefore considered to be related to immunosuppressive therapy or the activity of nephritis. Although we are uncertain as to what was the direct trigger for rapid onset of multiple keratosis, given that the patient still showed normal kidney function despite having proteinuria, immunosuppressive therapies may have led to the development of multiple porokeratosis in the present case.

<sup>☆</sup> Study conducted at the Fukushima Medical University, Fukushima, Japan.



**Figure 3** Histological examination showed dyskeratotic cells in the thinned epidermis with cornoid lamella, and absence of granular cell layer. Superficial perivascular lymphocytic infiltrate in the dermis was also observed (Hematoxylin & eosin, ×200).

### Financial support

None declared.

### Authors' contributions

Masato Ishikawa: Designed the study; performed the research and contributed to analysis and interpretation of data; wrote the initial draft of the manuscript; read and approved the final version of the manuscript.



Toshiyuki Yamamoto: Designed the study; assisted in the preparation of the manuscript; read and approved the final version of the manuscript.

### Conflicts of interest

None declared.

### References

1. Shoimer I, Robertson LH, Storwick G, Haber RM. Eruptive disseminated porokeratosis: a new classification system. *J Am Acad Dermatol.* 2014;71:398–400.
2. Bednarek R, Ezra N, Toubin Y, Linos K, Mousdicas N. Eruptive disseminated porokeratosis associated with corticosteroid-induced immunosuppression. *Clin Exp Dermatol.* 2015;40:753–6.
3. Raychaudhuri SP, Smoller BR. Porokeratosis in immunosuppressed and nonimmunosuppressed patients. *Int J Dermatol.* 1992;31:781–2.
4. Pérez-Crespo M, Betlloch I, Lucas-Costa A, Bañuls-Roca J, Jaime MN, Mataix J. Unusual evolution of giant porokeratosis developing in two renal transplant patients. *Int J Dermatol.* 2008;47:759–60.
5. Hernandez MH, Lai CH, Mallory SB. Disseminated porokeratosis associated with chronic renal failure: a new type of disseminated porokeratosis? *Arch Dermatol.* 2000;136:1568–9.

Masato Ishikawa \*, Toshiyuki Yamamoto 

*Department of Dermatology, Fukushima Medical University, Fukushima, Japan*

\* Corresponding author.

*E-mail:* [ishimasa@fmu.ac.jp](mailto:ishimasa@fmu.ac.jp) (M. Ishikawa).

Received 6 July 2020; accepted 8 August 2020

Available online 20 March 2022

<https://doi.org/10.1016/j.abd.2020.08.038>

0365-0596/ © 2022 Sociedade Brasileira de Dermatologia.

Published by Elsevier España, S.L.U. This is an open access article under the CC BY license (<http://creativecommons.org/licenses/by/4.0/>).

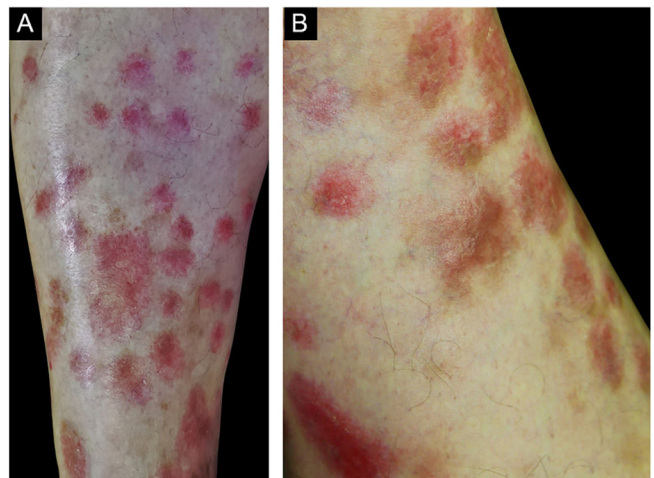
## Granulomatous arteritis limited to the skin: case report and etiologic differential diagnosis<sup>☆</sup>



Dear Editor,

Vasculitis constitutes a heterogeneous group of conditions characterized by inflammation in the blood vessel wall, with narrowing or occlusion of the vascular lumen. A 43-year-old man, without comorbidities, had presented multiple erythematous nodules on the anterior surface of the lower limbs for the past ten years, with outbreaks and remissions (Fig. 1). He had no local or systemic symptoms. A skin biopsy was performed and histopathology disclosed a nodular infiltrate with epithelioid histiocytes and multinucleated giant cells, on the wall and around a medium-caliber vessel, with occlusion

of the lumen by a fibrinoid thrombus (Figs. 2 and 3). Verhoeff-van Gieson staining demonstrated the presence of



**Figure 1** (A and B), Erythematous nodules on the extensor surface of the lower limbs.

<sup>☆</sup> Study conducted at the Hospital do Servidor Público Estadual de São Paulo, Instituto de Assistência Médica ao Servidor Público Estadual de São Paulo, São Paulo, SP, Brazil.