




- virus. Papular mucinosis (PM) in association with HIV infection. *Clin Exp Dermatol.* 2010;35:801–2.
3. Alves J, Matos D, Capitão-Mor M. Primary cutaneous mucinosis – a clinicopathological review. *J Port Soc Dermatol Venereol.* 2013;71:467–75.
 4. Rongioletti F. Lichen myxedematosus (papular mucinosis): new concepts and perspectives for an old disease. *Semin Cutan Med Surg.* 2006;25:100.
 5. Rongioletti F, Ghigliotti C, De Marchi R, Rebora A. Cutaneous mucinosis and HIV infection. *Br J Dermatol.* 1998;139:1077–9.
 6. Volpato MB, Jaime TJ, Proença MP, Gripp AC, Alves MFGS. Papular mucinosis associated with hypothyroidism. *An Bras Dermatol.* 2010;85:89–92.
 7. Banno H, Takama H, Nitta Y, Ikeya T, Hirooka Y. Lichen myxedematosus associated with chronic hepatitis C. *Int J Dermatol.* 2000;39:212–4.
 8. Depaire-Duclos F, Renuy F, Dandurand M, Guillot B. Papular mucinosis with rapid spontaneous regression in an HIV-infected patient. *Eur J Dermatol.* 1998;8:353.

Nathalia Hoffmann Guarda ^{a,*},
Renan Rangel Bonamigo ^{a,b},
Renata Heck ^a

^a *Sanitary Dermatology Outpatient Clinic, Secretaria de Saúde do Estado do Rio Grande do Sul, Porto Alegre, RS, Brazil*

^b *Faculty of Medicine, Universidade Federal do Rio Grande do Sul, Porto Alegre, RS, Brazil*

* Corresponding author.

E-mail: hofgan@pitt.edu (N.H. Guarda).

Received 22 August 2021; accepted 25 October 2021;
Available online 24 February 2023

<https://doi.org/10.1016/j.abd.2021.10.017>

0365-0596/ © 2023 Sociedade Brasileira de Dermatologia.

Published by Elsevier España, S.L.U. This is an open access article under the CC BY license (<http://creativecommons.org/licenses/by/4.0/>).

Papulopustular infantile acne treated with oral isotretinoin[☆]



Dear Editor,

Infantile acne is considered when it occurs between one and 16 months of age.¹ Topical retinoids, benzoyl peroxide at low concentrations, and oral antibiotics (except tetracyclines) are used in the treatment of children.²

This report describes the case of a two-month-old boy who presented papules, pustules, and a cyst on the malar region, bilaterally, as well as closed and open comedones, compatible with the diagnosis of infantile acne (Fig. 1). The laboratory hormonal evaluation of the child and mother (who also had severe acne) was normal. Initially, oral erythromycin was used for two months, oral cephadroxyl for another two months, as well as the fixed combination of adapalene and benzoyl peroxide associated with non-comedogenic emollients.

Despite the prolonged use of oral antibiotics and topical medications, progression of lesions and scar formation occurred. At seven months of age, oral isotretinoin was started at a dose of 0.5 mg/kg/day (target dose 960–1200 mg). The 10 mg capsule was frozen and half of the tablet was administered to the child in the milk.¹

After reaching the 150 mg/kg dose nine months later and with gradual adjustment according to weight gain (up to ¾ of the tablet), there was no disease activity (Fig. 2) throughout a 12-month follow-up. During treatment, the patient had mild cheilitis and xerosis, without laboratory alterations. As post-isotretinoin maintenance therapy, the fixed combina-

tion of adapalene and benzoyl peroxide was prescribed, as well as non-comedogenic emollients.

The androgenic hormonal laboratory investigation is mandatory in cases of refractory infantile acne, although most cases are not related to underlying endocrine diseases.^{1,3}

Oral isotretinoin, as well as topical therapy, are off-label treatments at this age; however, the many recently published cases demonstrate not only important clinical improvement in refractory cases but also their safe use in infants.^{3,4}

Acitretin is used in recessive congenital ichthyosis throughout life, since birth, being the confirmation test of retinoid safety in childhood. Early closure of epiphyses in children treated with oral retinoids is a rare event, associated with previous diseases, use of high doses, or prolonged treatment.² In the meantime, oral isotretinoin, when prescribed for refractory infantile acne, is a short-term treatment that requires low doses.⁴

The oral isotretinoin dose for infantile acne varies among publications between 0.2 and 2.0 mg/kg/day, with a total treatment period of five up to 14 months.¹ According to the latest acne consensus, the cumulative dose of isotretinoin should be the one in which complete clearing of lesions is attained, with drug maintenance for two more months, in contrast to the strict recommendation of reaching 120–150 mg/kg in all patients.⁵

Delay in the diagnosis of infantile acne is mainly due to the rarity of the disease at this age, as well as undertreatment and delay in the introduction of oral isotretinoin in these children.¹ It is therefore important that infants with severe, chronic acne, refractory to conventional treatment, be evaluated for underlying endocrinological disorders, not delaying drug use when there is resistance to oral antibiotics as well as the formation of scars.

[☆] Study conducted at the Hospital de Doenças Tropicais Dr. Anuar Aua, Goiânia, GO, Brazil.

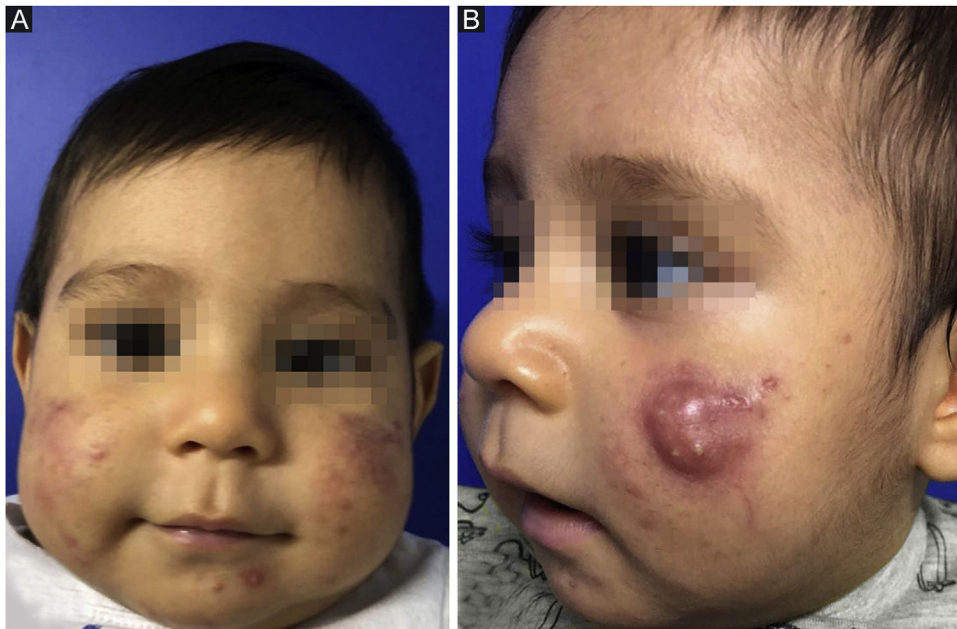

Figure 1 Infantile acne. (A) At two months of age, papules, pustules, and comedones on the face; (B) At seven months, even with the implemented therapy, the patient had a draining cyst, scars, and active papulopustular lesions.

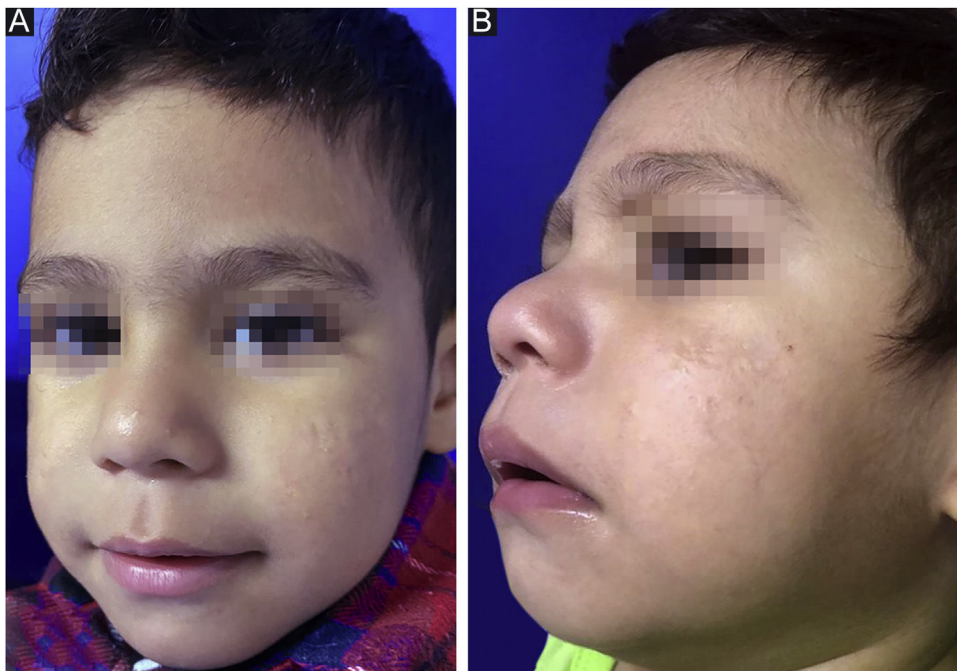

Figure 2 Infantile acne treated with oral isotretinoin. (A/B) One year after the end of treatment with oral isotretinoin, the patient shows residual normochromic scars.

Financial support

None declared.

Authors' contributions

Grasielle Silva Santos: Design and planning of the study; data survey, analysis, and interpretation of data; drafting and

editing of the manuscript; collection, analysis, and interpretation of data; intellectual participation in the propaedeutic and/or therapeutic conduct of the studied cases; critical review of the literature.

Mayra Ianhez: Design and planning of the study; data survey, analysis, and interpretation of data; critical review of important intellectual content; collection, analysis, and interpretation of data; effective participation in research orientation; intellectual participation in the propaedeutic

and/or therapeutic conduct of the studied cases; critical review of the literature; approval of the final version of the manuscript.

Helio Amante Miot: Critical review of important intellectual content; analysis and interpretation of data; effective participation in research orientation; intellectual participation in the propaedeutic and/or therapeutic conduct of the studied cases; critical review of the literature; approval of the final version of the manuscript.

Conflicts of interest

None declared.

References

1. Barnes CJ, Eichenfield LF, Lee J, Cunningham BB. A practical approach for the use of oral isotretinoin for infantile acne. *Pediatr Dermatol.* 2005;22:166–9.
2. Eichenfield LF, Krakowski AC, Piggott C, Del Rosso J, Baldwin H, Friedlander SF, et al. American Acne and Rosacea Society. Evidence-based recommendations for the diagnosis and treatment of pediatric acne. *Pediatrics.* 2013;131:S163–86.
3. Miller IM, Echeverría B, Torrelo A, Jemec GB. Infantile acne treated with oral isotretinoin. *Pediatr Dermatol.* 2013;30:513–8.
4. Brito MFM, Sant’Anna IP, Figueiroa F. Evaluation of the side effects of acitretin on children with ichthyosis - a one-year study. *An Bras Dermatol.* 2004;79:283–8.
5. Thiboutot DM, Dréno B, Abanmi A, Alexis AF, Araviiskaia E, Cabal MIB, et al. Practical management of acne for clinicians: An international consensus from the Global Alliance to Improve Outcomes in Acne. *J Am Acad Dermatol.* 2018;78:S1–23.

Grasielle Silva Santos ^a, Mayra Ianhez ^{a,*},
Hélio Amante Miot ^b

^a Hospital de Doenças Tropicais Dr Anuar Auad, Goiânia, GO, Brazil

^b Department of Dermatology and Radiotherapy, Universidade Estadual Paulista, Botucatu, SP, Brazil

Corresponding author.

E-mail: ianhez@hotmail.com (M. Ianhez).

Received 3 May 2021; accepted 24 May 2021;

Available online 15 February 2023

<https://doi.org/10.1016/j.abd.2021.05.026>

0365-0596/ © 2023 Sociedade Brasileira de Dermatologia.

Published by Elsevier España, S.L.U. This is an open access article under the CC BY license (<http://creativecommons.org/licenses/by/4.0/>).

Post-COVID-19 lichen planus annularis: report of a rare association[☆]



Dear Editor,

Since the beginning of the new coronavirus (SARS-CoV-2) pandemic, several cases of extrapulmonary involvement have been reported, including cardiovascular, gastrointestinal, neurological, and cutaneous manifestations. A wide variety of dermatological conditions related to COVID-19 infection have been reported;^{1,2} however, reports of lichen planus (LP) associated with COVID-19 are scarce in the literature.^{3,4}

A 56-year-old male patient complained of pruritic lesions that appeared on his lower limbs six months before. He mentioned that the lesions appeared approximately one week after the onset of COVID-19 infection symptoms, which was confirmed by RT-PCR. The patient had a mild respiratory clinical picture, without the need for hospitalization, and used ivermectin and hydroxychloroquine, prescribed at the service where he was originally treated. After the rash appeared, he used oral fluconazole and topical ketoconazole, with no improvement. The patient had a history of HIV infection, with an undetectable viral load for several years, without other comorbidities and with negative serology for syphilis, hepatitis B, and hepatitis C. He was under-

going regular treatment with lamivudine (3TC), tenofovir disoproxil fumarate (TDF) and dolutegravir (DTG), without recent changes in medications.

On dermatological examination, the lesions were clinically and dermoscopically compatible with LP (Figs. 1 and 2). He had no ungueal or oral mucosa lesions. Biopsies of two lesions were performed (Fig. 3), confirming the diagnosis of LP annularis after COVID-19 infection.

Lichen planus is an immune-mediated dermatosis of unknown cause, which affects less than 1% of the population, mainly middle-aged adults, and may affect the skin, hair, nails, and mucous membranes.⁵ Association with hepatitis C, other viral infections, vaccines, and autoimmune diseases such as vitiligo, dermatitis herpetiformis, and pemphigus has been reported.⁵ The annularis form is considered a rare variant of the LP. Although several skin manifestations have been associated with COVID-19, few cases of post-COVID-19 LP have been reported.^{3,4}

A possible association between HIV infection and LP has already been reported. In the present case, we consider that the LP was triggered by the COVID-19 infection, since the patient had been diagnosed with HIV 24 years before, without changes in the medications of chronic use, with the appearance of lichenoid lesions timely associated with COVID-19. SARS-CoV-2 infection can stimulate cytotoxicity by TCD8⁺ lymphocytes and Th17 cells, changes that also participate in the pathogenesis of LP, and this can persist even after the resolution of the triggering viral infection.⁴ Moreover, we do not consider LP as being triggered by the medications used during the coronavirus infection, since no reports of LP triggered by ivermectin or hydroxychloroquine use have been identified in a literature review, as well as

[☆] Study conducted at the Hospital das Clínicas, Ribeirão Preto Faculty of Medicine, Universidade de São Paulo, Ribeirão Preto, SP, Brazil.