

rence or malignant change during the prospective follow-up period.

In conclusion, HP on the vulvar site is a diagnostically challenging benign entity. The tumor is quite rare, and physicians do not gain sufficient experience to suspect it. Dermoscopy of this lesion, even if not decisive in the diagnosis, can be useful in the differential diagnosis of important neoplasms such as melanoma and SCC. However, in these cases, the diagnostic gold standard remains the histopathology.

### Financial support

None declared.

### Authors' contributions

Vincenzo De Giorgi: Study concept and design; analysis and interpretation of data; drafting of the manuscript; critical revision of the manuscript for important intellectual content; study supervision.

Biancamaria Zuccaro: Acquisition of data.

Flavia Silvestri: Acquisition of data.

Federico Venturi: Acquisition of data.

Vincenzo De Giorgi had full access to all of the data in the study and takes responsibility for the integrity of the data and the accuracy of the data analysis.

### Conflicts of interest

None declared.

### References

1. El-Khoury J, Renald MH, Plantier F, Avril MF, Moyal-Barracco M. Vulvar hidradenoma papilliferum (HP) is located on the sites of mammary-like anogenital glands (MLAGs): Analysis of the photographs of 52 tumors. *J Am Acad Dermatol.* 2016;75:380–4.
2. Tosti G, Salvini C, Barisani A, Grazi R, Pirola S, Cantisani C, et al. Vulvar hidradenoma papilliferum: a clinical and dermoscopic study. *Clin Exp Dermatol.* 2020;45:1035–9.
3. De Giorgi V, Salvati L, Barchielli A, Caldarella A, Gori A, Scarfi F, et al. The burden of cutaneous adnexal carcinomas and the risk of associated squamous cell carcinoma: a population-based study. *Br J Dermatol.* 2019;180:565–73.
4. De Giorgi V, Massi D, Salvini C, Mannone F, Cattaneo A, Carli P. Thin melanoma of the vulva: A clinical, dermoscopic-pathologic case study. *Arch Dermatol.* 2005;141:1046–7.
5. De Giorgi V, Salvini C, Massi D, Raspollini MR, Carli P. Vulvar basal cell carcinoma: Retrospective study and review of literature. *Gynecol Oncol.* 2005;97:192–4.

Vincenzo De Giorgi \*, Biancamaria Zuccaro ,  
Flavia Silvestri , Federico Venturi 

Section of Dermatology, Department of Health Sciences,  
University of Florence, Florence, Italy

\* Corresponding author.

E-mail: [vincenzo.degiorgi@unifi.it](mailto:vincenzo.degiorgi@unifi.it) (V. De Giorgi).

Received 11 October 2021; accepted 5 November 2021;

Available online 24 March 2023

<https://doi.org/10.1016/j.abd.2021.11.014>

0365-0596/ © 2023 Sociedade Brasileira de Dermatologia.

Published by Elsevier España, S.L.U. This is an open access article under the CC BY license (<http://creativecommons.org/licenses/by/4.0/>).

## Keloid formation following ear piercing through the transitional zone<sup>☆</sup>



Dear Editor,

Ear piercing is one of the major risk factors for keloid formation. The majority of piercing is performed through the soft tissue of the earlobe only (zone 1). In addition, it may be performed through the ear cartilage (zone 2) or the transitional zone (zone 3) between the ear cartilage and earlobe.<sup>1</sup> The incidence of complications due to transcartilagenous piercing is approximately 35% because of the avascular nature of auricular cartilage.<sup>1</sup>

There are no studies regarding transitional zone keloids in the literature. We hypothesized that ear piercing through the transitional zone should be assessed as if through the cartilage zone.

We herein present three cases of keloid formation after ear piercing through the transitional zone of the ear. None of our patients had a personal or familial history of keloid or hypertrophic scar formation. The diagnosis was confirmed by histopathological examination for all patients. The clinical features of the patients are presented in [Table 1](#). Patient 1 had a total of four piercings, two in the right earlobe, one in the left earlobe, and one in the right transitional zone. Patient 2 had a total of five piercings, two in the right earlobe, two in the left earlobe, and one in the right transitional zone. All piercings were performed simultaneously in both patients. However, no keloid formation was observed at the earlobe piercing points, in which transcartilagenous piercing did not exist ([Fig. 1](#)). Patient 3 had only one piercing in the right transitional zone ([Fig. 2](#)). A combination of intralesional corticosteroid administered at 40 mg/mL over intervals of 3–4 weeks for 16 weeks and cryosurgery were performed. Early recurrence was not observed in any patients during the first year of follow-up.

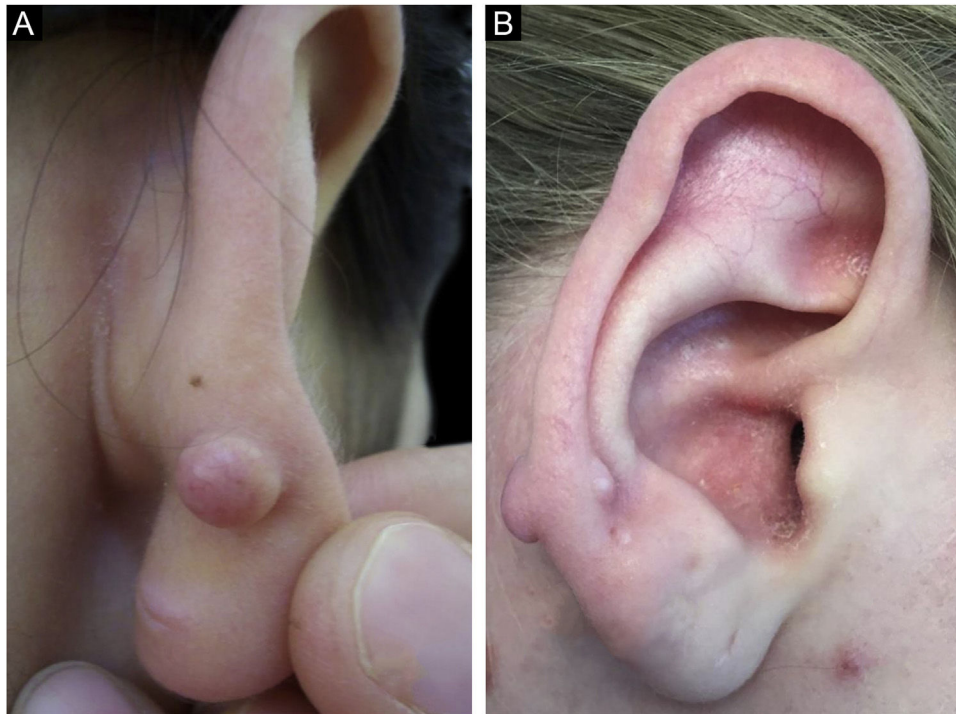
Piercing jewelry material, earring backs, the type of piercing procedure, and complications related to piercing at the time of the procedure may contribute to keloid formation.<sup>2</sup> None of our patients had a complication related to piercing at the time of the procedure. In our cases,

<sup>☆</sup> Study conducted at the Department of Dermatology and Venereology at Bursa Uludag University School of Medicine, Bursa, Turkey.

**Table 1** Clinical features of the patients.

Patient no	Sex	Age at the ear piercing (yrs)	Time between piercing and keloid formation	Localization of keloid	Other complications due to piercing
1	F	17	<1 y	R, P, zone 3	None
2	F	20	<1 y	R, AP, zone 3	None
3	M	34	<1 y	R, A, zone 3	None

F, Female; M, Male; y, year; yrs, years; R, Right; P, Posterior; A, Anterior; AP, Anterior and Posterior.



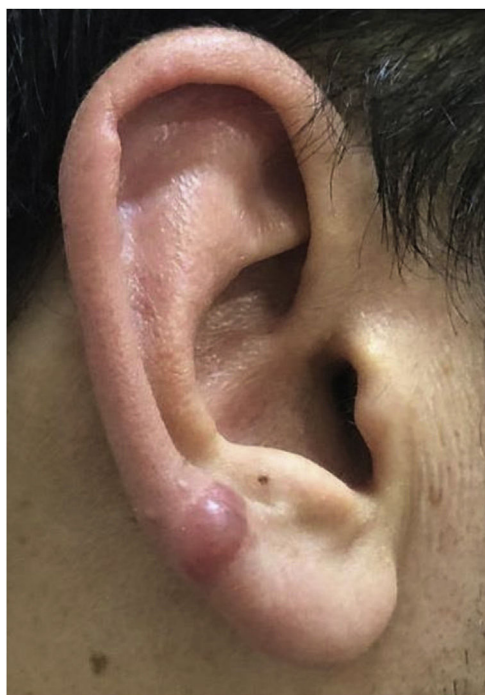**Figure 1** Keloid formation following piercing through the transitional zone in patient 1 (A) and patient 2 (B). There is no keloid formation at the earlobe piercing points in both patients.

keloid formation was more likely to be associated with a cartilage injury.

Currently, the upregulation of cartilage oligomeric matrix protein (COMP), a noncollagenous extracellular matrix glycoprotein, has been shown in keloidal tissue, suggesting that COMP facilitates keloid formation by accelerating collagen deposition.<sup>3</sup> In addition, it has been reported that multiple hereditary exostoses, which are characterized by the development of multiple benign osteochondrinous masses, were found to be a risk factor for keloid formation after surgical excision of osteochondromas representing another association of keloids and chondrocytes.<sup>4</sup>

It was reported that there was no difference regarding piercing-related complications between the earlobe and the cartilaginous part of the ear.<sup>1,5</sup> This result may be attributed to earlobe piercing being performed more frequently than cartilage or transitional zone piercing.

Assessing ear piercings through the transitional zone as if through the cartilage zone may be more appropriate. Transitional and cartilage zones of the ear may be avoided during ear piercing to prevent the development of keloid formation.



**Figure 2** Keloid formation following piercing through the transitional zone in patient 3.

### Financial support

This research did not receive any specific grant from funding agencies in the public, commercial, or not-for-profit sectors.

### Author's contribution

All authors (Ozge Zorlu, Serkan Yazici, Şaduman Balaban Adım) have been actively involved in study conception and planning, critical literature review, data collection, analysis and interpretation, research orientation, preparation and writing of the manuscript, and review of the manuscript. All authors read and approved the final version of the manuscript.

### Conflicts of interest

None declared.

### References

1. Simplot TC, Hoffman HT. Comparison between cartilage and soft tissue ear piercing complications. *Am J Otolaryngol.* 1998;19:305–10.
2. Hochman B, Isoldi FC, Silveira TS, Borba GC, Ferreira LM. Does ear keloid formation depend on the type of earrings or piercing jewellery? *Australas J Dermatol.* 2015;56:e77–9.
3. Inui S, Shono F, Nakajima T, Hosokawa K, Itami S. Identification and characterization of cartilage oligomeric matrix protein as a novel pathogenic factor in keloids. *Am J Pathol.* 2011;179:1951–60.
4. Hosalkar H, Greenberg J, Gaugler RL, Garg S, Dormans JP. Abnormal scarring with keloid formation after osteochondroma excision in children with multiple hereditary exostoses. *J Pediatr Orthop.* 2007;27:333–7.
5. Fijałkowska M, Kasielska A, Antoszewski B. Variety of complications after auricle piercing. *Int J Dermatol.* 2014;53:952–5.

Ozge Zorlu <sup>a,\*</sup>, Serkan Yazici <sup>a</sup>, Şaduman Balaban Adım <sup>b</sup>

<sup>a</sup> *Department of Dermatology and Venereology, Bursa Uludağ University School of Medicine, Bursa, Turkey*

<sup>b</sup> *Department of Pathology, Bursa Uludağ University School of Medicine, Bursa, Turkey*

\* Corresponding author.

E-mail: [zorluz@gmail.com](mailto:zorluz@gmail.com) (O. Zorlu).

Received 22 July 2021; accepted 6 August 2021;  
Available online 28 March 2023

<https://doi.org/10.1016/j.abd.2021.08.016>

0365-0596/ © 2023 Sociedade Brasileira de Dermatologia.

Published by Elsevier España, S.L.U. This is an open access article under the CC BY license (<http://creativecommons.org/licenses/by/4.0/>).

## Pemphigus vulgaris associated with nasoseptal perforation, ocular conjunctival herpes infection and milia formation<sup>☆</sup>

Dear Editor,

We report a 60-year-old woman who was diagnosed with pemphigus vulgaris (PV) associated with uncommon pre-



sentations, i.e., nasal mucosal involvement with septal perforation, ocular conjunctival involvement of herpes simplex virus (HSV) infection, and milia on the re-epithelialized skin. We will discuss each association based on the results of our laboratory examinations.

Clinical examination revealed erosive skin lesions mainly on the face, trunk, and limbs, as well as mucosal lesions on the tongue, gingivae, and palate (Fig. 1A), and hyperemia on the left conjunctiva. Erosions and crusts in the nasal mucosa, and anterior nasoseptal perforation were also detected. Additionally, milia were observed on the skin of the face and shoulders, which were previously affected by PV (Fig. 1B).

Histopathology showed suprabasal acantholysis for biopsies taken from the chest and from the nasal septum (Fig. 2A). IgG deposition on keratinocyte cell surfaces

<sup>☆</sup> Study conducted at the Laboratory of Dermatology, University Hospital, Ribeirão Preto Medical School, University of São Paulo, Brazil, and at the Department of Dermatology, Kurume University School of Medicine, and Kurume University Institute of Cutaneous Cell Biology, Fukuoka, Japan.