

LETTER - TROPICAL/INFECTIOUS AND PARASITIC DERMATOLOGY

Cutaneous protothecosis in a solid organ transplanted patient[☆]



Dear Editor,

A 35-year-old woman, with a history of cretinism and chronic kidney disease secondary to congenital urological pathology, received a kidney transplant at the age of 30. At 5 years, due to graft rejection, she required a new transplant and was started on prednisone 20 mg/day, tacrolimus 16 mg/day, and mycophenolate mofetil 250 mg every 8 hours.

During her admission for bacteremia secondary to urinary tract infection, an erythematous plaque with diffuse borders and discrete asymptomatic superficial scaling was observed on the anterior and lateral sides of her left leg (Figs. 1 and 2). Laboratory investigations showed leukocytes of 4900 mm³ with a relative neutrophilia of 94%. Arterial and venous Doppler ultrasound of the left lower limb showed lymphedema and increased echogenicity of the subcutaneous tissue. PET-CT revealed an increase in the density of the subcutaneous cellular tissue, accompanied by an inflammatory process. Skin biopsy was performed for histopathology and culture of bacteria, mycobacteria, and fungi. The first presented large, rounded structures, with multiple cytoplasmic septa, some with a morula-like appearance, and numerous sporangia with internal septa forming endospores (Fig. 3 and 4). In culture, creamy white colonies were observed, some rough with depressed centers, compatible with *Prototheca* spp. (Fig. 5).

Systemic treatment with liposomal Amphotericin B 200 mg/day was started, with an improvement of the skin lesions. Fourteen days later, she switched to itraconazole 200 mg every 8 hours for 3 days and then continued at 200 mg every 12 hours. It evolved in a torpid way with partial improvement and intermittent worsening. At 9 months, a new skin culture was performed where the sensitivity of *Prototheca* was verified, and treatment was changed to fluconazole 200 mg every 12 hours and minocycline 100 mg every 12 hours.

Ultimately, she developed septic shock related to a urinary tract infection caused by carbapenemase-producing *Klebsiella pneumoniae*. Antibiotic treatment was adminis-

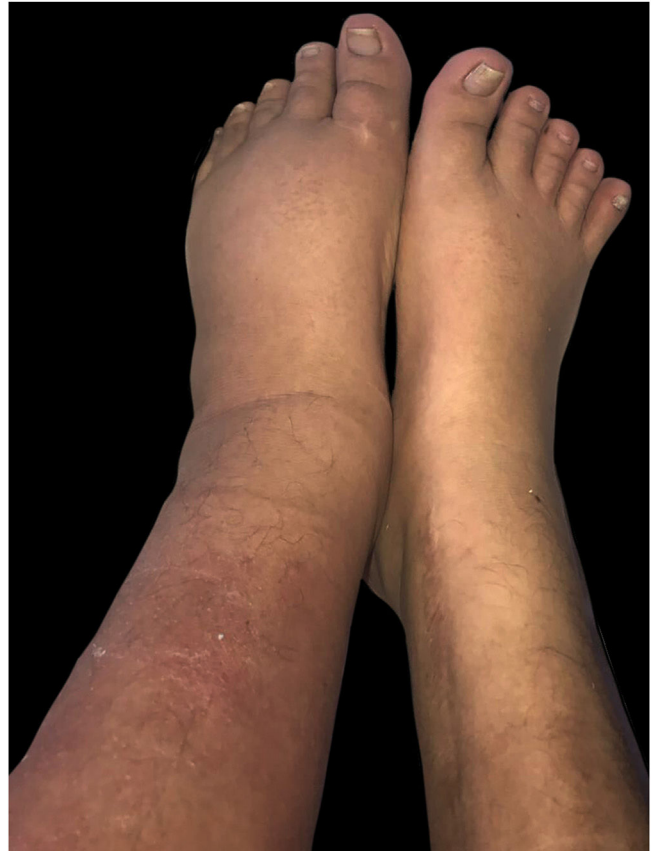

Figure 1 Asymmetry of the lower limbs due to an increase in the circumference of the left leg associated with erythema on its anterior region

tered, but despite this, the patient developed multi-organ failure and died.

Protothecosis is a rare infection caused by algae of the species *Prototheca* spp. Within the species of the *Prototheca* genus, *Prototheca wickerhamii* and *zopfii* are the ones that most frequently affect immunocompromised hosts.^{1,2}

Prototheca infection ranges from indolent and localized skin involvement, soft tissue infection, olecranon bursitis in immunocompetent patients, to devastating disseminated infection with algemia and visceral infiltration with high mortality in immunocompromised hosts due to transplant, diabetes, HIV, and hematologic diseases.^{2,3} The cutaneous form represents the most frequent manifestation (3 out of 4 patients). The lesions usually appear in areas exposed

[☆] Study conducted at the Italian Hospital of Buenos Aires, CABA, Argentina.

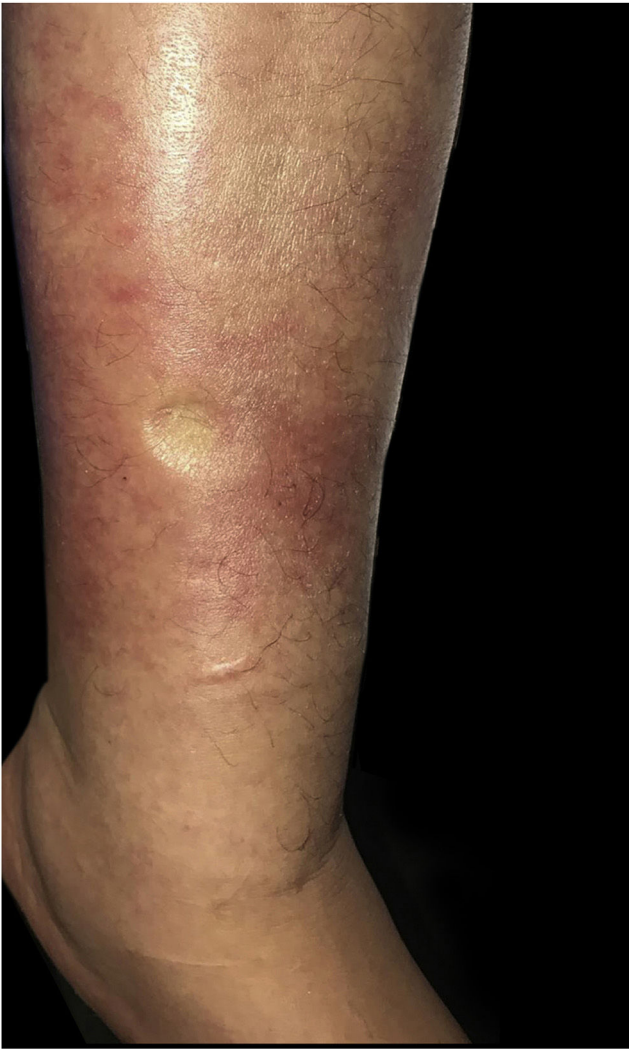

Figure 2 Erythematous and edematous plaque with diffuse borders on left leg. Edema with positive Godet's sign

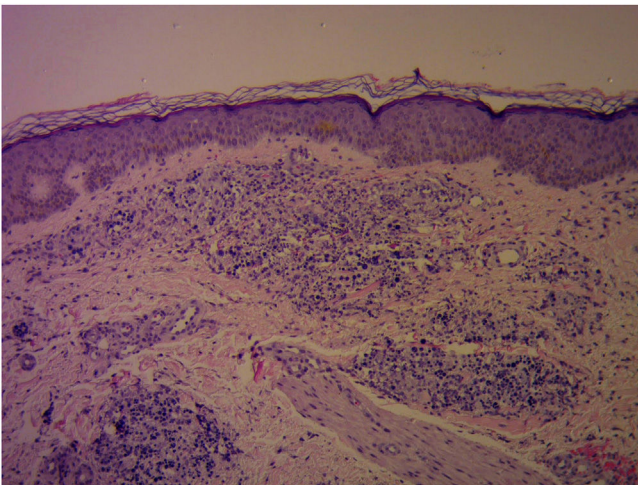


Figure 3 Granulomatous dermal infiltrate consisting of lymphocytes, histiocytes, multinucleated giant cells, and rounded structures, isolated or grouped, of different sizes, inside histiocytes and giant cells (Hematoxylin & eosin, $\times 100$)

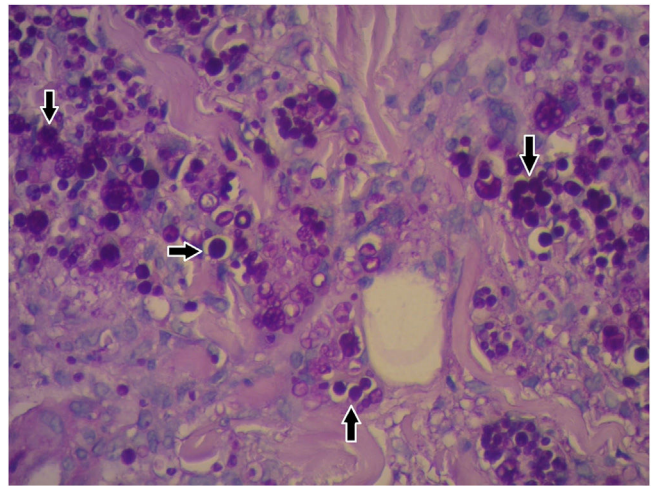


Figure 4 Histopathological characteristics (Hematoxylin & eosin, $\times 400$): Rounded structures larger than the surrounding cells and multiple cytoplasmic septa, which gives them a morula-like appearance. Sporangia highlighted

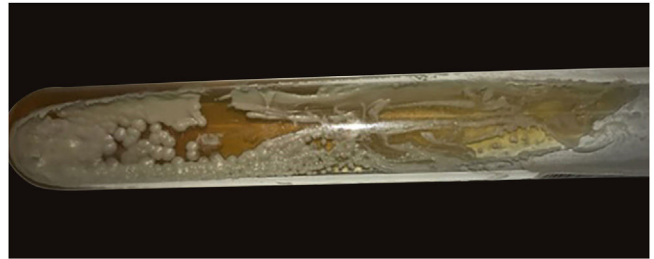

Figure 5 In culture, creamy white colonies were observed, some rough with depressed centers, compatible with *Prototheca* spp

to traumatic implantation. It usually presents with poorly defined erythematous plaques, although less frequently it can manifest with nodular, pustular, warty, and ulcerated lesions.

Diagnosis is made by clinical suspicion, detection of characteristic structures in skin cultures, and microscopic examination. The definitive diagnosis of infection is usually based on the morphological identification of the organisms in culture preparations in wet slides and/or direct identification in tissue samples as in the reported case.¹⁻⁴

Its prognosis is good in almost 70% of cases. On the other hand, when it presents in a disseminated form, it has a worse prognosis, with high mortality.^{1,5} The most commonly used medications are antifungals, including amphotericin B and systemic azoles. Amphotericin B is currently the first-line treatment in disseminated cases and in patients with severe underlying diseases or immunosuppression.⁶⁻⁹

In conclusion, protothecosis is an infrequent infection with nonspecific skin manifestations, so in the presence of plaques, nodules, ulcerated or warty lesions in immunosuppressed patients, a skin biopsy should be performed for culture and histopathology to detect infectious agents. The initiation of adequate treatment prevents the progression of the disease.⁵⁻¹⁰

Financial support

None declared.

Authors' contributions

Anama Di Prinzio: The study concept and design; writing of the manuscript.

Marina Ruf: The study concept and design; intellectual participation in the propaedeutic and/or therapeutic conduct of the studied cases.

Ana C. Torre: Data collection, or analysis and interpretation of data.

Sofia V. Duran Daza: Writing of the manuscript or critical review of important intellectual content.

Victoria I. Volonteri: Data collection.

Viviana Flores: Data collection.

Luis D. Mazzuoccolo: Final approval of the final version of the manuscript.

Conflicts of interest

None declared.








Acknowledgement

We thank Dr. Victoria Volonteri for her collaboration with the histological images of the patient.

References

1. Góes LDM, Monteiro VS, Souza ATO. Case for diagnosis. Ulcer and papular lesions in a patient with diabetes mellitus. *Protothecosis. An Bras Dermatol.* 2021;96:613–6.

2. Kwong JC, Ward PB, Johnson PD. Cutaneous protothecosis in a patient with hypogammaglobulinemia. *Med Mycol Case Rep.* 2013;2:132–3.
3. Zhang QQ, Li L, Zhu LP, Zhao Y, Wang YR, Zhu JH. Cutaneous protothecosis in patient with diabetes mellitus and review of published case reports. *Mycopathologia.* 2012;173:163–71.
4. Fong K, Tee SI, Ho MSL, Pan JY. Cutaneous protothecosis in a patient with previously undiagnosed HIV infection. *Austral J Dermatol.* 2014;56:71–3.
5. Tseng HC, Chen CB, Ho JC, Cheng YW, Huang HW, Sun PL. Clinicopathological features and course of cutaneous protothecosis. *J Eur Acad Dermatol Venereol.* 2018;32:1575–83.
6. Teh JS, Wilke AE, Overstall SM, Teng JC, Chin R, Couper JM, et al. Prototheca wickerhamii breast implant infection after reconstructive surgery: a new level of complexity. *Med Mycol Case Rep.* 2021;34:22–6.
7. Silva PCG, Silva SBC, Lima RB, D'Acri AM, Lupi O, Martins CJ. Cutaneous protothecosis - Case report. *An Bras Dermatol.* 2013;88:183–5.
8. Rui K. Emergence of fungal-like organisms: prototheca. *Mycopathologia.* 2020;185:747–54.
9. Todd JR, Matsumoto T, Ueno R, Murugaiyan J, Britten A, King JW, et al. Medical phycolgy 2017. *Med Mycol.* 2018;56:5188–204.
10. Kano R. Emergence of fungal-like organisms: Prototheca. *Mycopathologia.* 2020;185:747–54.

Anama Di Prinzio *, Marina Ruf , Ana C. Torre , Sofia V. Duran Daza , Victoria I. Volonteri , Viviana Flores , Luis D. Mazzuoccolo 

Italian Hospital of Buenos Aires, CABA, Argentina

* Corresponding author.

E-mail: anama.diprinzio@hospitalitaliano.org.ar (A. Di Prinzio).

Received 8 September 2022; accepted 7 October 2022
Available online 27 April 2023

<https://doi.org/10.1016/j.abd.2022.10.008>

0365-0596/ © 2023 Sociedade Brasileira de Dermatologia.

Published by Elsevier España, S.L.U. This is an open access article under the CC BY license (<http://creativecommons.org/licenses/by/4.0/>).

Secondary syphilis concomitant with primary lesion and early neurosyphilis in a kidney transplant recipient[☆]



Dear Editor,

Treponema pallidum, subspecies *pallidum*, is the causative agent of syphilis. Syphilis can be transmitted through sexual contact, blood transfusion, solid organ transplantation, and from mother to child.^{1,2} The rising incidence of syphilis is a global public health problem.³ Despite the large number

of people undergoing kidney transplantations (KTx), data on syphilis in this population are scarce.^{4–9}

A 24-year-old man presented to the emergency room in July 2020 with a painless genital ulcer for the preceding 20 days (Fig. 1A). Subsequently, multiple non-pruritic and painless erythematous papules with peripheral desquamation appeared. These papules had a symmetrical distribution, located on the trunk (Fig. 1B), upper limbs, and palmo-plantar region (Fig. 2A). He also had odynophagia and right peripheral facial palsy (Fig. 2B). He underwent kidney transplantation 18 months prior to the presentation. Immunosuppression included tacrolimus, sodium mycophenolate, and prednisone. He reported being heterosexual and denied sexual intercourse in the 3 months prior to presentation, or any previous episodes of syphilis. The serum treponemal Chemiluminescence Immunoassay (CLIA) test of the recipient before KTx was nonreactive (Table 1), as was

[☆] Study conducted at the Department of Infectious Diseases, Dermatology, Diagnostic Imaging and Radiotherapy, Faculty of Medicine, Universidade Estadual Paulista, Botucatu, SP, Brazil