

Financial support

None declared.

Authors' contributions

Rubén Linares-Navarro: Approval of the final version of the manuscript; critical literature review; data collection, analysis, and interpretation; effective participation in research orientation; intellectual participation in propaedeutic and/or therapeutic; management of studied cases; manuscript critical review; preparation and writing of the manuscript; study conception and planning.

Pedro Sánchez-Sambucety: Approval of the final version of the manuscript; critical literature review; data collection, analysis, and interpretation; effective participation in research orientation; intellectual participation in propaedeutic and/or therapeutic; management of studied cases; manuscript critical review; preparation and writing of the manuscript; study conception and planning.

Manuel Ángel Rodríguez-Prieto: Approval of the final version of the manuscript; critical literature review; data collection, analysis, and interpretation; effective participation in research orientation; intellectual participation in propaedeutic and/or therapeutic; management of studied cases; manuscript critical review; preparation and writing of the manuscript; study conception and planning.

Conflicts of interest

None declared.

References

1. Pižem J, Stojanović L, Luzar B. Melanocytic lesions with eczematous reaction (Meyerson's phenomenon) - a histopathologic analysis of 64 cases: melanocytic lesions with eczematous reaction. *J Cutan Pathol.* 2012;39:901–10.
2. Seque CA, Enokihara MMSS, Porro AM, Tomimori J. Skin manifestations associated with COVID-19. *An Bras Dermatol.* 2022;97:75–88.
3. Scharf C, Di Brizzi EV, Pellerone S, Liguori M, Giorgio CMR, Argenziano G. Nevocentric erythema multiforme after SARS-CoV-2 vaccine. *J Eur Acad Dermatol Venereol.* 2022;36:e30–2.
4. Loh J, Kenny P. Meyerson phenomenon. *J Cutan Med Surg.* 2010;14:30–2.
5. Knight JS, Caricchio R, Casanova JL, Combes AJ, Diamond B, Fox SE, et al. The intersection of COVID-19 and autoimmunity. *J Clin Invest.* 2021;131:e154886.

Rubén Linares-Navarro *, Pedro Sánchez-Sambucety , Manuel Ángel Rodríguez-Prieto 

Department of Dermatology, University Hospital of León, León, Spain

*Corresponding author.

E-mail: rlinares@saludcastillayleon.es (R. Linares-Navarro).

Received 19 September 2022; accepted 8 November 2022

Available online 27 April 2023

<https://doi.org/10.1016/j.abd.2022.11.002>

0365-0596/ © 2023 Sociedade Brasileira de Dermatologia.

Published by Elsevier España, S.L.U. This is an open access article under the CC BY license (<http://creativecommons.org/licenses/by/4.0/>).

Multinucleate cell angiohistiocytoma: a diagnostic challenge[☆]



Dear Editor,

A 33-year-old male patient presented with multiple erythematous-brown papules measuring 1 to 5 mm, disseminated on the upper limbs, trunk and thighs (Fig. 1). Dermoscopy disclosed the presence of a peripheral network and a central homogeneous pink area (Fig. 2). The condition had started two years before when he sought another Service and received a diagnosis of secondary syphilis, confirmed by non-treponemal (VDRL 1:64) and treponemal tests (positive FTA-ABS). He was treated on two occasions with three doses of benzathine penicillin, with no improvement of the skin condition (VDRL after treatments - 1:16). Diagnostic hypotheses were made of generalized multinucleate cell angiohistiocytoma (MCA) and eruptive dermatofibromas.

Histopathology showed proliferated capillary vessels with dilated lumen (Fig. 3A) and multinucleate giant

cells with ample cytoplasm interspersed with fibroblasts, lymphocytes, and histiocytes (Figs. 3B and 3C). Immunohistochemical analysis showed: immunoexpression of CD138 in the cytoplasmic membrane of the interstitial plasmocytes that permeated the lymphoid aggregates (Fig. 4A); cytoplasmic immunoexpression of Factor XIIIa in spiky multinucleate giant cells (Fig. 4B); positive expression of CD68 and CD163 in dermal histiocytes and negative in endothelial cells; CD31 positivity in the vascular component and negative immunoexpression of S100, establishing the diagnosis of MCA.

After he was instructed about the condition, the patient chose not to undergo treatment for aesthetic purposes and returned after one year with spontaneous significant improvement in the number, pigmentation, and size of the lesions (Fig. 5).

Discussion

Multinucleate cell angiohistiocytoma is a rare benign fibrous histiocytic proliferation, described in 1985.¹ It often presents as well-circumscribed, dome-shaped erythematous-brown papules clustered on the hands, wrists, face, or legs. Localized, multifocal and generalized variants have been described, with the localized variant being the most common. Approximately 150 reported cases were

[☆] Study conducted at the Universidade Federal de São Paulo, São Paulo, SP, Brazil.

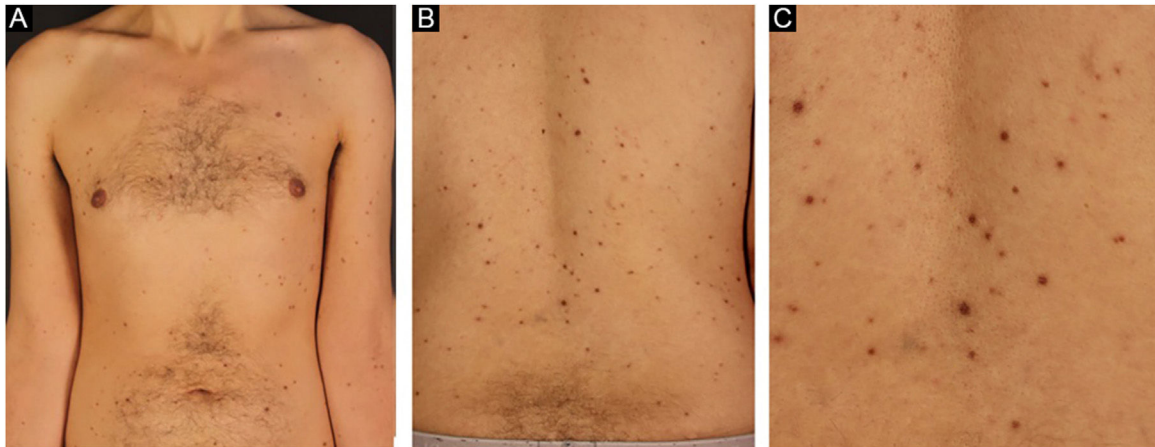


Figure 1 Brownish-erythematous papules affecting the upper limbs and trunk (A and B) and at closer view (C)

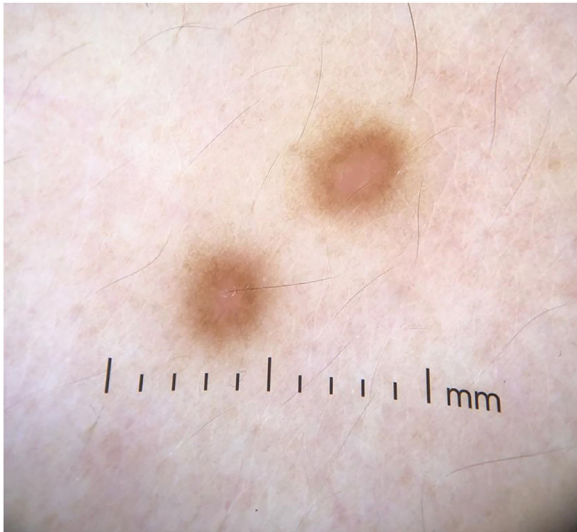


Figure 2 Dermoscopy showing a peripheral network with a central homogeneous pink area

found, with only 15 of the generalized variant.² There is an important female predilection in the localized and multifocal variants, whereas males and females are equally affected in the generalized variant.³

Since the first description of MCA, several hypotheses have been proposed for its etiology and pathogenesis. Most authors believe it to be a reactive process and reports of spontaneous remission further support this hypothesis.^{4,5} The reported case may represent MCA manifesting after *Treponema pallidum* infection. Another theory proposes that MCA arises under the influence of female hormones due to the identification of estrogen receptor alpha expression in the interstitial and multinucleate cells of lesions in several patients.⁶ This theory would also explain why MCA occurs more frequently in women in the localized and multifocal variants. Other authors consider MCA a variant of dermatofibroma⁷ or associate it with an altered immune status.²

Dermoscopy can show some similarities with dermatofibromas, such as whitish areas and a fine peripheral reticulated pattern. Diffuse reddish areas with blurred edges, which likely represent the characteristic vascular dilation, may also be found.⁸

Histopathology shows proliferation of dilated capillaries, fibrous stroma with thickened collagen bundles, and the presence of multinucleate giant cells. The overlying epidermis may be normal or hyperplastic. The presence of at least three of the described in the adequate clinical context is highly specific for MCA and allows differentiation from fibrous papule and dermatofibroma. The criteria considered for the diagnosis were: a) Presence of atypical and multinucleate fibroblasts with at least two nuclei; b) Presence of superficial parallel dermal fibrosis; c) Presence of thickened superficial papillary dermal vessels; d) Absence of perifollicular fibrosis.⁹

Regarding immunohistochemistry, the multinucleate cells are typically negative for factor VIII and CD34 and positive for vimentin and factor XIIIa. There is a positive correlation between CD68-positive expression of endothelial cells and lesion size, and an inverse correlation between CD68-positive expression on multinucleate cells and the development of multiple lesions.⁴

The biological behavior of MCA is progressive in most cases, albeit benign, with spontaneous improvement being rare. Treatment can be carried out for aesthetic purposes. The currently available therapeutic options include topical or intralesional corticosteroids, surgical excision, cryotherapy, argon laser, intense pulsed light, and CO₂ laser.¹⁰ In conclusion, the authors describe a rare case of MCA possibly triggered by *Treponema pallidum* infection and suspected by dermoscopic findings. Because it is rare, it is important that dermatologists and pathologists are able to recognize it for a better approach and to provide recommendations to the patient. Multiple treatment options are available to improve the aesthetic appearance, most of which are supported by case reports.

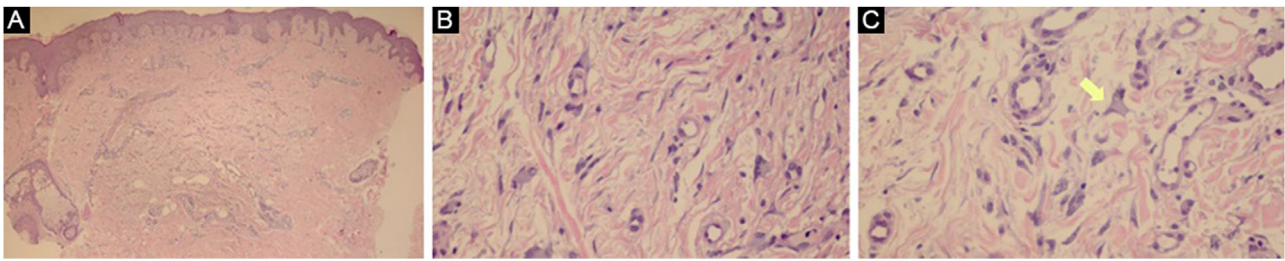


Figure 3 (A) The superficial reticular dermis shows proliferated capillaries with dilated lumen (Hematoxylin & eosin, $\times 40$). (B) In some regions, multinucleate cells with ample cytoplasm interspersed with fibroblasts, lymphocytes, and histiocytes are observed. (Hematoxylin & eosin, $\times 400$). (C) Some multinucleate cells have a spiky cytoplasm (arrow; Hematoxylin & eosin, $\times 400$)

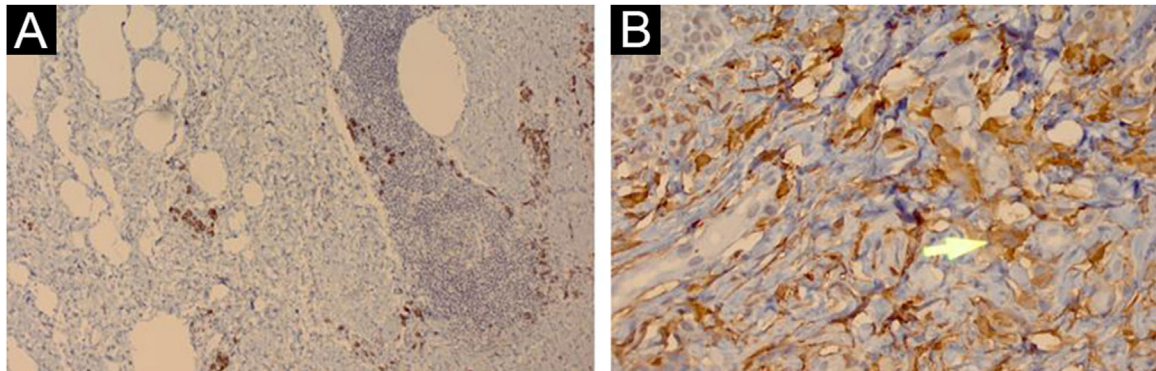


Figure 4 (A) Immunohistochemical analysis showing immunopositivity of CD138 in the cytoplasmic membrane of interstitial plasma cells that permeate the lymphoid aggregates ($\times 100$). (B) Cytoplasmic immunopositivity of factor XIIIa in spiky multinucleate cells (arrow; $\times 400$)

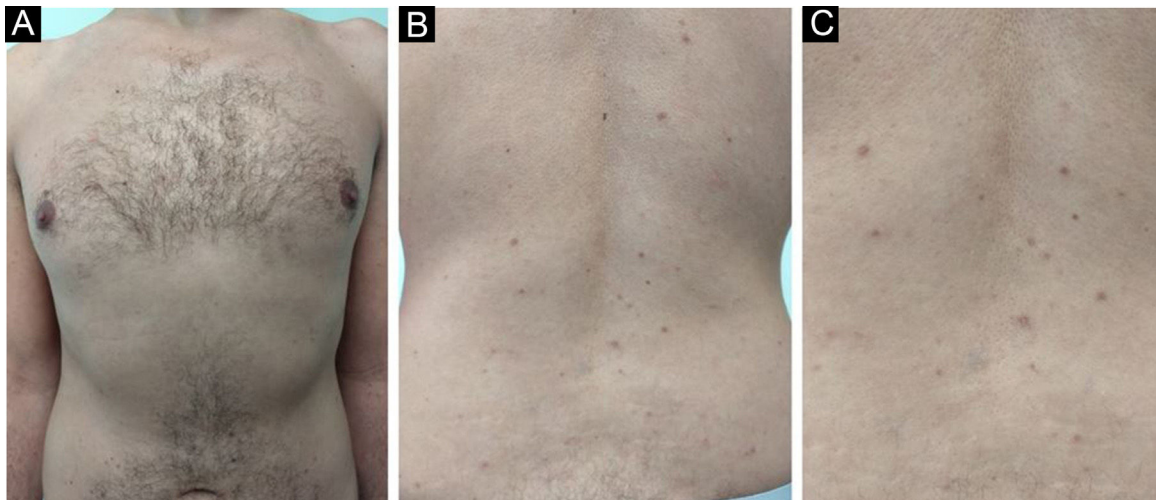


Figure 5 Decrease in the number, pigmentation and size of the lesions after one year in the anterior thoracic region (A) and back region (B and C)

Financial support

None declared.

Authors' contributions

Patricia Mayumi Ogawa: Design and planning of the study; drafting and editing of the manuscript; collection, analysis and interpretation of data; critical review of the literature.

Maria Cristina Arci Santos: Approval of the final version of the manuscript; drafting and editing of the manuscript; collection, analysis and interpretation of data; effective participation in research orientation; critical review of the manuscript.

Nilceo Schwery Michalany: Approval of the final version of the manuscript; collection, analysis and interpretation of data; intellectual participation in the propaedeutic and/or

therapeutic conduct of the studied cases; effective participation in research orientation; critical review of the manuscript.

Renato Shintani Hikawa: Approval of the final version of the manuscript; collection, analysis and interpretation of data; design and planning of the study; intellectual participation in propaedeutic and/or therapeutic conduct of studied cases; effective participation in research orientation; critical review of the manuscript.

Conflicts of interest

None declared.

Acknowledgments

The authors would like to thank Dr. Mílvia Maria Simões e Silva Enokihara for the analysis, interpretation, and photographs of the anatomopathological data and for her effective participation in research orientation.

References

- Smith NP, Jones WE. Multinucleate cell angiohistiocytoma – a new entity. *Br J Dermatol.* 1985;113:5.
- Jia QN, Qiao J, Qu T. Generalized multinucleate cell angiohistiocytoma with possible origin from fibroblasts: a clinicopathological study of 15 cases. *J Dermatol.* 2021;48:114–9.
- Wang M, Abdul-Fattah B, Wang C, Zhao Y, Qu X, Al-Murieh M, et al. Generalized multinucleate cell angiohistiocytoma: case report and literature review. *J Cutan Pathol.* 2017;44:125–34.
- Frew JW. Multinucleate cell angiohistiocytoma: clinicopathological correlation of 142 cases with insights into etiology and pathogenesis. *Am J Dermatopathol.* 2015;37:222–8.
- Wilson JE, Cerio R, Smith NP. Multinucleate cell angiohistiocytoma: an acquired vascular anomaly to be distinguished from Kaposi's sarcoma. *Br J Dermatol.* 1990;122:651–63.
- Cesinaro AM, Roncati L, Maiorana A. Estrogen receptor alpha overexpression in multinucleate cell angiohistiocytoma: new insights into the pathogenesis of a reactive process. *Am J Dermatopathol.* 2010;32:655–9.
- Doshi-Chougule BN, Gust A, Mentzel T, Böer-Auer A. Multinucleate cell angiohistiocytoma with hypertrophic nerves. *J Cutan Pathol.* 2013;40:1048–53.
- Valerón-Almazán P, Dehesa L, Santana N, Vilar J, Carretero G. Dermoscopic features of multinucleate cell angiohistiocytoma: a variant of dermatofibroma? *Actas Dermosifiliogr.* 2011;102:69–71.
- Roy SF, Dong D, Myung P, McNiff JM. Multinucleate cell angiohistiocytoma: a clinicopathologic study of 62 cases and proposed diagnostic criteria. *J Cutan Pathol.* 2019;46:563–9.
- Moradi Tuchayi S, Garibyan L, Lee KC. Successful treatment of multinucleate cell angiohistiocytoma with fractionated ablative CO2 laser. *JAAD Case Rep.* 2019;5:297–9.

Patricia Mayumi Ogawa ^{a,*},
 Maria Cristina Arci Santos ^a,
 Nilceo Schwery Michalany ^b,
 Renato Shintani Hikawa ^a

^a Department of Dermatology, Universidade Federal de São Paulo, Escola Paulista de Medicina, São Paulo, SP, Brazil

^b Department of Pathology, Universidade Federal de São Paulo, Escola Paulista de Medicina, São Paulo, SP, Brazil

* Corresponding author.

E-mail: patricia.ogawa@huhsp.org.br (P.M. Ogawa).

Received 2 December 2021; accepted 17 January 2022

Available online 22 May 2023

<https://doi.org/10.1016/j.abd.2022.01.017>

0365-0596/ © 2023 Sociedade Brasileira de Dermatologia.

Published by Elsevier España, S.L.U. This is an open access article under the CC BY license (<http://creativecommons.org/licenses/by/4.0/>).

Sarcoid reaction in eyebrow tattooing: a complication of a common cosmetic procedure[☆]



Dear Editor,

In the last decades, facial pigmentation techniques for aesthetic purposes have become common. Among them is eyebrow tattooing or micropigmentation. Unlike traditional tattoos, in which the pigment is deposited in the deeper layers of the dermis, in micropigmentation, the semi-permanent pigment is deposited in the upper layer of the dermis. Adverse reactions to this technique include infection, contact dermatitis, granulomatous reactions, and Koebner phenomenon.¹

A 30-year-old female patient, with a history of previous bariatric surgery, without other comorbidities, complained of raised eyebrows for three months. She had repeatedly undergone micropigmentation of the region over the past four years, the last being 14 months before. She denied any systemic symptoms. On examination, she had raised plaques on the topography of the eyebrows, especially on the right, in addition to areas of alopecia (Fig. 1A). At dermoscopy, homogeneous orange-brown areas and rarefied hairs were seen (Fig. 2). The remainder of the physical examination was normal. Complementary tests including serum calcium level, electrocardiogram, chest X-ray, serum protein electrophoresis, and tuberculin skin test were normal.

Histopathology showed non-caseating chronic granulomatous dermatitis with a sarcoid pattern (Fig. 3); acid-fast bacillus (AFB) and fungal tests were negative. With the diagnosis of sarcoid reaction secondary to the tattooing of the eyebrows, therapy with doxycycline 100mg/day and fludrocortidone occlusive treatment was performed for 15 days. The patient missed the reassessment appointment and returned after three months with complete regression of the

[☆] Study conducted at the Sanitary Dermatology Outpatient Clinic, Secretaria de Saúde do Estado do Rio Grande do Sul, Porto Alegre, RS, Brazil.