





3. Poblet E, Jiménez F, Pascual A, Piqué E. Frontal fibrosing alopecia versus lichen planopilaris: a clinicopathological study. *Int J Dermatol.* 2006;45:375–80.
4. Lis-Święty A, Brzezińska-Wcisto L. Frontal fibrosing alopecia: a disease that remains enigmatic. *Postepy Dermatol Alergol.* 2020;37:482–9.
5. Bergqvist C, Vitoligo Ezzedine K. a focus on pathogenesis and its therapeutic implications. *J Dermatol.* 2021;48:252–70.

Jéssica Pauli Damke \*, Bruna Ossanai Schoenardie , Rochelle Figini Maciel , Juliano Peruzzo 

*Serviço de Dermatologia, Hospital de Clínicas de Porto Alegre, Porto Alegre, RS, Brazil*

\* Corresponding author.

E-mail: [jpdamke@gmail.com](mailto:jpdamke@gmail.com) (J.P. Damke).

Received 27 August 2021; accepted 14 October 2021

Available online 19 July 2023

<https://doi.org/10.1016/j.abd.2021.10.018>

0365-0596/ © 2023 Published by Elsevier España, S.L.U. on behalf of Sociedade Brasileira de Dermatologia. This is an open access article under the CC BY license (<http://creativecommons.org/licenses/by/4.0/>).

## Frontal fibrosing alopecia: report of four sisters<sup>☆</sup>



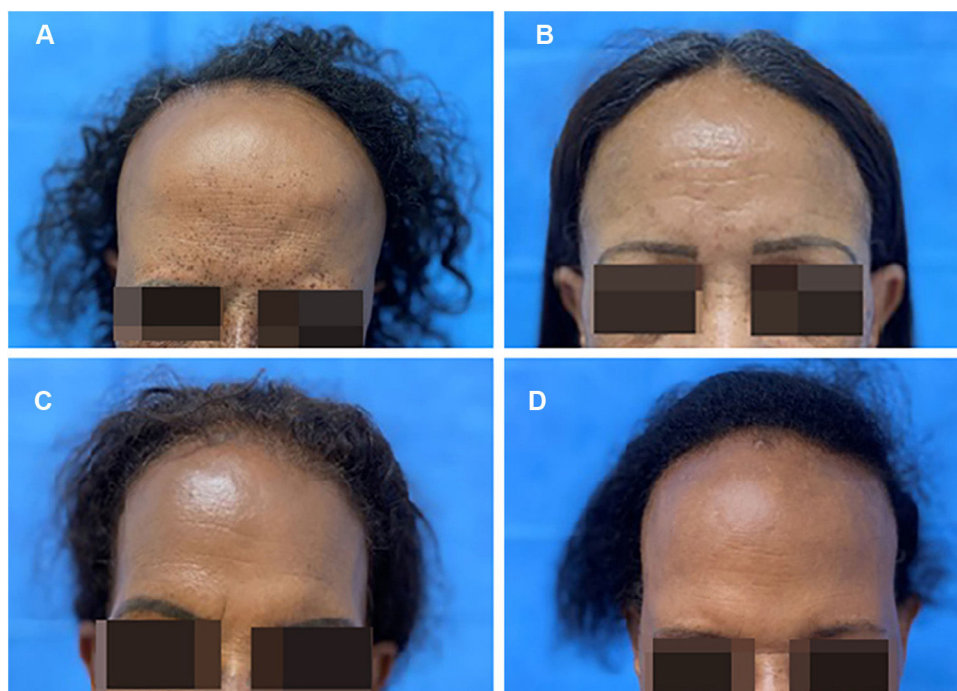
Dear Editor,

Frontal fibrosing alopecia (FFA) belongs to the group of lymphocytic cicatricial alopecias and was first described in 1994 by Kossard.<sup>1</sup> Clinically, retraction of the frontotemporal hair implantation line is observed, often associated with loss of eyebrows and, in some cases, loss of hair from other parts of the body.<sup>2</sup>

There is a predilection for the female sex and Caucasian individuals, particularly in the postmenopausal period.<sup>3</sup> The

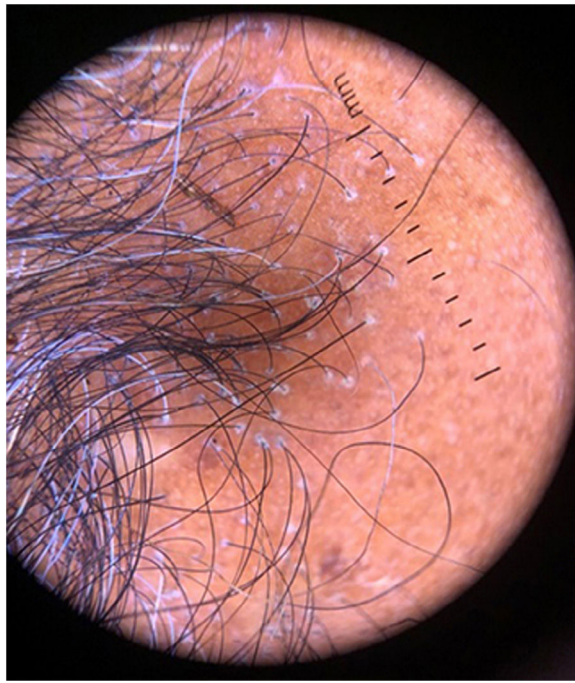
first reports of FFA in individuals from the same family appeared in 2010 when the occurrence of the disease was described in two sisters.<sup>4</sup> The etiopathogenesis of FFA is still unknown, but the genetic predisposition has been reinforced by its association with some class I human leukocyte antigen (HLA) alleles. As the incidence has been increasing over the years, it is postulated that current environmental triggers may act on a genetic predisposition, driving the th1/JAK-STAT inflammation profile in FFA.<sup>2</sup>

This family consists of five black sisters, aged between 56 and 66 years, all of which have already gone through menopause. The youngest of them came to the dermatology outpatient clinic complaining of thinning hair and, after

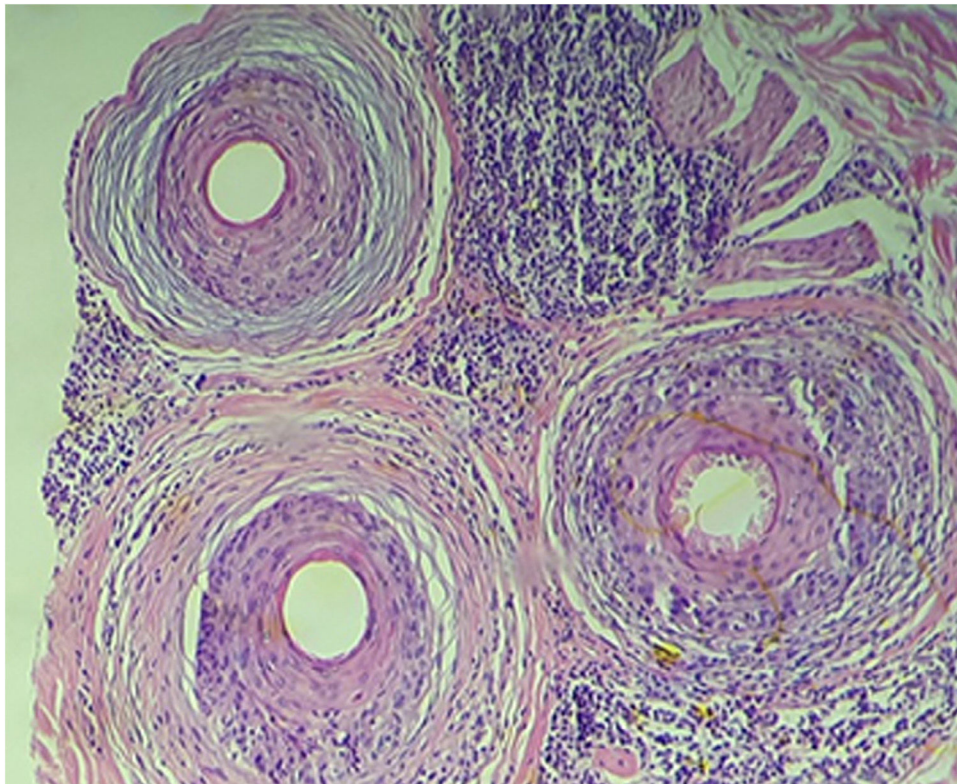


**Figure 1** (A–D) Clinical presentation of the four sisters affected by frontal fibrosing alopecia (FFA)

<sup>☆</sup> Study conducted at the Complexo Hospitalar Padre Bento de Guarulhos, Guarulhos, SP, Brazil.



**Figure 2** Trichoscopy of one of the patients corroborating the diagnosis. Peri-hair shaft desquamation, follicular units with only one emerging hair shaft, absence of follicular orifices, absence of vellus hairs and ivory-white background with erythema in the area of fibrosis. All patients had a similar pattern



**Figure 3** Histopathology of the scalp, isthmus level; (Hematoxylin & eosin,  $\times 100$ ). Cicatricial alopecia with perifollicular concentric fibrosis, lymphocytic inflammation in and around the follicular epithelium and presence of apoptosis. The infundibulum and bulb region did not show any inflammation

**Table 1** Clinical data of four sisters with frontal fibrosing alopecia

Patient	Age (years)	Phototype	Age at symptoms onset (years)	Clinical subtype	Lichen planus pigmentosus	Papules on the face	Eyebrow alopecia	Menopause (years)	Comorbidities	Hair treatments
1	56	V	40	I	Present	Absent	Present	55	SAH, unspecified arthritis	Previous hair straightening (adolescence)
2	61	V	59	I	Present	Absent	Present	50	DM, Dyslipidemia, Bipolarity, Smoking	Hair straightening and dying
3	64	V	60	I	Present	Absent	Present	48	DM, Glaucoma	Hair straightening and dying
4	66	V	62	I	Present	Absent	Absent	50	SAH, Hyperthyroidism, Glaucoma	Hair straightening and dying

DM, Diabetes mellitus; SAH, Systemic arterial hypertension.

being asked about her family history, she reported that she had sisters with a similar condition, and thus, all of them were invited to come for an appointment to be evaluated. After the clinical examination, it was found that four of them were affected by FFA (Figs. 1 and 2), and the diagnosis was also confirmed by anatomopathological examination (Fig. 3). They are from and currently live in the urban area of São Paulo; they lived together until adolescence, and all of them have undergone hair straightening procedures since childhood. They were born to the same parents, who are already deceased and were evaluated through photographs, which showed the mother's hair without alterations, whereas the father had signs of androgenetic alopecia. Only one of the sisters, aged 63, had a normal scalp.

The affected patients showed the same clinical pattern, classified as the linear pattern or type I, when there is linear retraction of the hair implantation line. The age at the disease onset ranged from 40 to 62 years. The youngest sister had the most advanced condition, being the only one with disease onset before menopause. She had a history of using regular sunscreen protection since adolescence, longer than the other sisters, who reported irregular use for a few years. Three of them lacked eyebrow hairs, and all had facial lesions suggestive of lichen planus pigmentosus, which is often associated with FFA, especially in patients with a higher phototype.<sup>5</sup> Among the comorbidities most often related to FFA, one had arthritis (unspecified) and another had hyperthyroidism. The clinical data are detailed in Table 1.

Since its description, FFA has been reported mainly in Caucasian individuals. Due to the lack of data in the literature, it cannot be stated with conviction whether the prevalence in African descendants is actually lower or if this population has been less studied when compared to Caucasians.<sup>5</sup>

FFA is a relatively recent disease and its prevalence has been increasing in recent years. Since African descent ethnicity and the genetic component have been described in a minority of cases, the authors highlight the relevance of reporting this family series.

### Financial support

None declared.

### Authors' contributions

Jéssica Vianna Starek: Approval of the final version of the manuscript; drafting and editing of the manuscript; critical review of the literature; critical review of the manuscript.

Thaís Petry Raszl: Approval of the final version of the manuscript; drafting and editing of the manuscript; critical review of the literature; critical review of the manuscript.

Samar Mohamad El Harati Kaddourah: Approval of the final version of the manuscript; critical review of the manuscript.

### Conflicts of interest

None declared.

### References

1. Kossard S. Postmenopausal frontal fibrosing alopecia. scarring alopecia in a pattern distribution. *Arch Dermatol.* 1994;130:1407.
2. Ramos PM, Anzai A, Duque-Estrada B, Farias DC, Melo DF, Mulinari-Brenner F, et al. Risk factors for frontal fibrosing alopecia: a case-control study in a multiracial population. *J Am Acad Dermatol.* 2021;84:712–8.

3. Lis-Święty A, Brzezińska-Wcisło L. Frontal fibrosing alopecia: a disease that remains enigmatic. *Postepy Dermatol Alergol.* 2020;37:482–9.
4. Navarro-Belmonte MR, Navarro-López V, Ramírez-Boscà A, Martínez-Andrés MA, Molina-Gil C, González-Nebreda M, et al. Case series of familial frontal fibrosing alopecia and a review of the literature. *J Cosmet Dermatol.* 2015;14:64–9.
5. Porriño-Bustamante ML, Fernández-Pugnaire MA, Arias-Santiago S. Frontal fibrosing alopecia: a review. *J Clin Med.* 2021;10:1805.

Jéssica Vianna Starek \*, Thaís Petry Raszl 

*Department of Dermatology, Complexo Hospitalar Padre Bento, Guarulhos, SP, Brazil*

Samar Mohamad El Harati Kaddourah 

*Department of Dermatology, General Dermatology Outpatient Clinic, Trichoses, Complexo Hospitalar Padre Bento, Guarulhos, SP, Brazil*

\* Corresponding author.

E-mail: [jessicastarek@gmail.com](mailto:jessicastarek@gmail.com) (J.V. Starek).

Received 5 September 2021; accepted 21 February 2022

Available online 17 July 2023

<https://doi.org/10.1016/j.abd.2022.02.009>

0365-0596/ © 2023 Sociedade Brasileira de Dermatologia.

Published by Elsevier España, S.L.U. This is an open access article under the CC BY license (<http://creativecommons.org/licenses/by/4.0/>).

## Linear syngnocyadenoma papilliferum of the limb: a rare localization of an uncommon tumour<sup>☆</sup>



Dear Editor,

Syringocystadenoma Papilliferum (SCAP) is a benign adnexal neoplasm that most frequently arises from an organoid nevus on the head and neck. It usually occurs during childhood or adolescence, varying in morphological character from smooth and flat to verrucous form. Most reported cases in the literature are single lesions presenting as a solitary raised warty plaque, and less commonly multiple papules. Here we report a case of multiple SCAP with a warty surface presenting on the limb distributed along a Blaschko line and without pre-existing lesions in an adult.

A 45-year-old female presented with several pink nodules on the left upper limb for seven years. The lesions were pruriginous and prone to bleed after scratching. Physical examination revealed multiple, verrucous papules, measuring 1 to 2.5 cm in the left upper extremity following a line of Blaschko. Central umbilication was seen in several lesions (Fig. 1A, B). She was misdiagnosed at another hospital with *verruca vulgaris*, laser was used to remove some of the lesions but soon recurred. One of the lesions was surgically excised and histopathology was performed. Features of SCAP were identified, with the tumor located in the superficial layer of the dermis without connection to the overlying epidermis, composed of cystadenoma-like structures and folded papillary structures. The cystic spaces and papillary

structures were lined with single columnar epithelium and surrounded by a layer of small cuboidal myoepithelial cells, forming a special double-layer structure (Fig. 1C, D). DNA tested for Human Papillomavirus (HPV) was negative. After excision, there was no recurrence or new lesions at the 3-month and 6-month follow-ups. As the patient did not want to excise the other papules, we arranged for a subsequent visit after 6 months.

SCAP was first described by Stokes in 1917. The pathogenesis of SCAP remains unclear, HPV DNA and mutations in the RAS/mitogen-activated protein kinase signaling pathway have been detected.<sup>1,2</sup> In our case we failed to identify HPV infection though the lesions show verrucous growths. SCAP frequently arises in puberty within organoid nevi in the head and neck region. As far as we have observed, there have been 17 previous cases of linear SCAP reported in the literature in English, and only two of these cases developed in adults, aged 21 and 34 respectively. The reported 17 cases include 10 females and 7 males, 6 cases occurred in the head and neck, 5 cases were in the trunk, 5 cases were in the extremities and one case was in the inguinal fold. In the extremities, 3 were found on the leg and 2 on the upper limb.<sup>3–5</sup> The unique features of our case are Blaschkolinear distribution, the localization on the upper limb, late-onset in an adult, and the tumor without connection to the overlying epidermis. So far, neither organoid naevus nor epidermal naevus has been demonstrated in the linear form of SCAP. Therefore, multiple linear SCAP may represent a distinct clinical form, the relationship of linear SCAP with organoid naevus or other adnexal tumors needs further investigation.

<sup>☆</sup> Study conducted at the Chengdu Second People's Hospital, Chengdu, Sichuan, China.