

Financial support

None declared.

Authors' contributions

Claudia Suárez: Approval of the final version of the manuscript; intellectual participation in propaedeutic and/or therapeutic management of studied cases; manuscript critical review; preparation and writing of the manuscript.

Gonzalo Hevia: Approval of the final version of the manuscript; critical literature review; manuscript critical review; preparation and writing of the manuscript.

Catalina Silva-Hirschberg: Approval of the final version of the manuscript; critical literature review; manuscript critical review; preparation and writing of the manuscript.

Alex Castro: Approval of the final version of the manuscript; manuscript critical review; preparation and writing of the manuscript.

Conflicts of interest

None declared.

References

- Burlando M, Herzum A, Cozzani E, Paudice M, Parodi A. Can methotrexate be a successful treatment for unresponsive generalized annular elastolytic giant cell granuloma? Case report and review of the literature. *Dermatol Ther.* 2021;34:e14705.
- Pons Benavent M, Porcar Saura S. Visual Dermatology: annular elastolytic giant cell granuloma. *J Cutan Med Surg.* 2022;26:98.
- Jeha GM, Luckett KO, Kole L. Actinic granuloma responding to doxycycline. *JAAD Case Rep.* 2020;6:1132–4.
- Tas B, Caglar A, Ozdemir B. Treatment with doxycycline of generalized annular elastolytic giant cell granuloma associated with borrelia burgdorferi infection. *West Indian Med J.* 2015;64:447–51.
- Errichetti E, Cataldi P, Stinco G. Dermoscopy in annular elastolytic giant cell granuloma. *J Dermatol.* 2019;46:e66–7.
- Diep D, Calame A, Cohen PR. Tinea corporis masquerading as a diffuse gyrate erythema: case report and a review of annular lesions mimicking a dermatophyte skin infection. *Cureus.* 2020;12:e8935.

Claudia Suárez ^a, Gonzalo Hevia ^{a,b},
Catalina Silva-Hirschberg ^{a,b,*}, Alex Castro ^c

^a Department of Dermatology, Hospital Padre Hurtado, Santiago, Chile

^b Department of Dermatology, Facultad de Medicina, Clínica Alemana, Universidad del Desarrollo, Santiago, Chile

^c Department of Pathology, Facultad de Medicina, Clínica Alemana, Universidad del Desarrollo, Santiago, Chile

* Corresponding author.

E-mail: casilvah@udd.cl (C. Silva-Hirschberg).

Received 19 January 2022; accepted 24 February 2022

Available online 29 June 2023

<https://doi.org/10.1016/j.abd.2022.02.010>

0365-0596/ © 2023 Sociedade Brasileira de Dermatologia.

Published by Elsevier España, S.L.U. This is an open access article under the CC BY license (<http://creativecommons.org/licenses/by/4.0/>).

Cardiac rhabdomyomas as prenatal diagnostic markers of tuberous sclerosis complex[☆]



Dear Editor,

Tuberous Sclerosis Complex (TSC) is a rare genetic neurocutaneous syndrome, with a frequency of 1/6,000–10,000 live births, characterized by hamartomas and multiple skin manifestations.¹ Adequate diagnosis is challenging, therefore the TSC Alliance² convened on criteria, which include cardiac rhabdomyomas, a type of hamartomas, as a main diagnostic feature.³ These tumors are diagnosed via ultrasound during the second and third trimester, correlating with TSC in 70%–90% of the cases.^{3,4}

The authors present three male patients with a prenatal diagnosis of cardiac rhabdomyomas and postnatal confirmation of TSC. Dermatologic examination of all patients revealed multiple hypopigmented macules in the trunk and

scalp (Fig. 1), more evident under Wood's lamp (Fig. 1). Patient A had no family history of TSC and presented fetal arrhythmia caused by multiple cardiac tumors located in the left ventricle, which regressed during the first year of life. Patient B presented a fetal asymptomatic solitary rhabdomyoma, which also regressed during the first year. In this case, the authors noticed his mother had multiple hamartomas of the face (Fig. 2) so after further examination, she was also diagnosed with TSC. Patient C had three cardiac rhabdomyomas diagnosed in the third trimester causing cardiac flow obstruction. Three months after birth, he was admitted due to seizures, which led to the confirmation of tuberous tumors in the brain and retinal hamartomas. Despite medical efforts, he had a fatal outcome. The diagnosis of TSC in all patients was based on two major clinical criteria:³ hypomelanotic macules (≥ 3 , at least 5 mm in diameter) and cardiac rhabdomyomas. Cardiac rhabdomyomas are the most frequent childhood primary heart tumors in the general population.³ Despite their benign nature, they may cause complications such as arrhythmias, outflow obstruction, pericardial effusion, cardiac compression, and fetal hydrops. TSC should be suspected when multiple, clearly demarcated, hyperechoic ovoid tumors are found. The most frequent location is the interventricular septum. If pos-

[☆] Study conducted at the Neonatal Maternal Hospital "Minister Dr. Ramon Carrillo", Cordoba, Argentina.

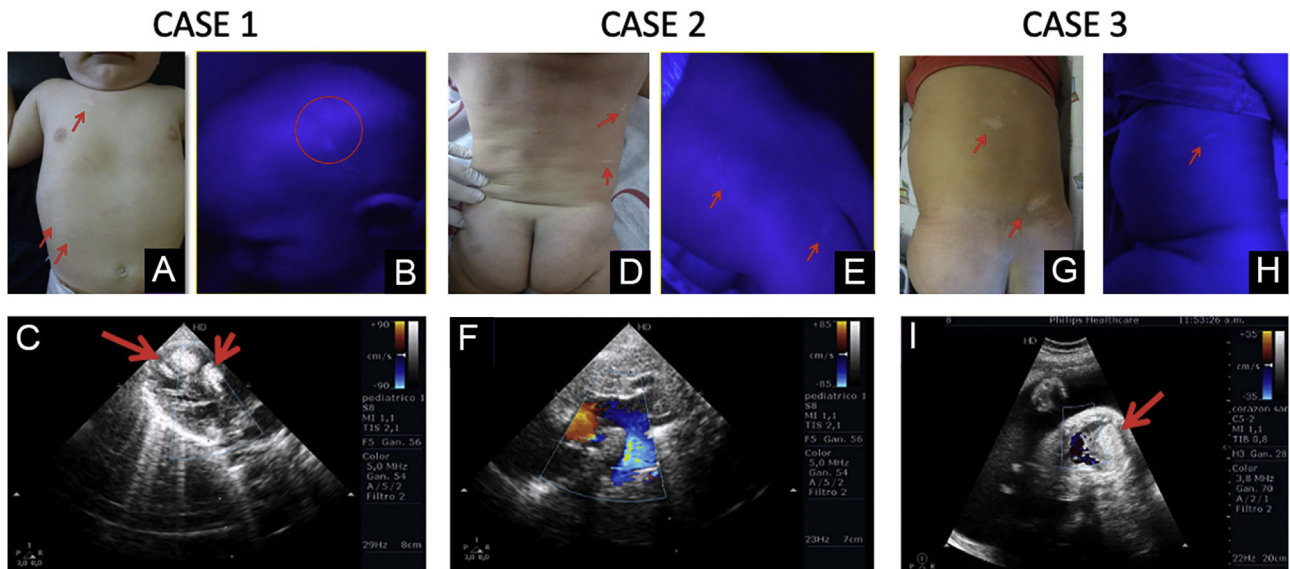


Figure 1 (A-I) Clinical images at physical examination, under Wood's lamp and sonographic imaging of cardiac rhabdomyomas of each case

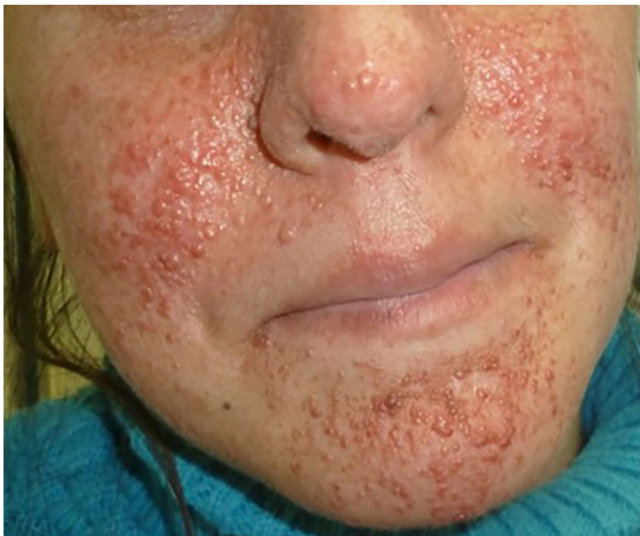

Figure 2 Case B's mother shows multiple hamartomas of the face

sible, searching for hamartomas in other locations with fetal MRI is suggested.^{1,5} Also, genetic testing assessment of three generations, along with a thorough dermatologic exam of relatives is indicated. When performed, a histological description of the tumors presents myocytes containing high quantities of glycogen, known as spider cells.³

Fetal prognosis is dependent on effective intrauterine monitoring and an adequate birth plan. Up to 85% of the cases do not need medical or surgical treatment since most have partial or complete regression from birth to adolescence.⁵ While skin findings might not be evident at birth, periodic dermatology consults are required in the search for angiofibromas, ungual fibromas, hypomelanotic

macules and/or Shagreen patch.³ These cases exemplify the importance of identifying rhabdomyomas, to help prepare for postnatal care, counsel parents and through adequate family history, identify affected relatives^{1,3} of this rare neurocutaneous syndrome.

Financial support

None declared.

Authors' contributions

Virginia Ruth Lopez Gamboa: Approval of the final version of the manuscript; critical literature review; data collection, analysis, and interpretation; effective participation in research orientation; intellectual participation in propaedeutic and/or therapeutic management of studied cases; manuscript critical review; preparation and writing of the manuscript; study conception and planning.

Mariel Giovo: Approval of the final version of the manuscript; critical literature review; data collection, analysis, and interpretation; effective participation in research orientation; intellectual participation in propaedeutic and/or therapeutic management of studied cases; manuscript critical review; study conception and planning.




Victor Francucci: Approval of the final version of the manuscript; data collection, analysis, and interpretation; effective participation in research orientation; manuscript critical review.

Conflicts of interest

None declared.

References

1. Gu X, Han L, Chen J, Wang J, Hao X, Zhang Y, et al. Antenatal screening, and diagnosis of tuberous sclerosis complex by fetal echocardiography and targeted genomic sequencing. *Medicine (Baltimore)*. 2018;97:e0112.
2. Pasieczna M, Kolesnik A, Królicki L, Duczkowski M, Bekiesinska-Figatowska M, Szymkiewicz-Dangel J. Fetal echocardiography gives a clue for the maternal diagnosis of tuberous sclerosis complex. *J Clin Ultrasound*. 2019;1–3.
3. Hinton RB, Prakash A, Romp RL, Krueger DA, Knilans TK, International Tuberous Sclerosis Consensus Group. Cardiovascular manifestations of tuberous sclerosis complex and summary of the revised diagnostic criteria and surveillance and management recommendations from the International Tuberous Sclerosis Consensus Group. *J Am Heart Assoc*. 2014;3:e001493.
4. Ozeren S, Cakiroglu Y, Doger E, Caliskan E. Sonographic diagnosis of fetal cardiac rhabdomyomas in two successive pregnancies in a woman with tuberous sclerosis. *J Clin Ultrasound*. 2012;40:179–82.
5. Pipitone S, Mongioli M, Grillo R, Gagliano S, Sperandeo V. Cardiac rhabdomyoma in intrauterine life: clinical features and natural history. A case series and review of published reports. *Ital Heart J*. 2002;3:48–52.

Virginia Ruth Lopez Gamboa ^{a,d,*}, Mariel Giovo ^b, Victor Francucci ^c

^a *Departamento de Dermatología, Collegiate Sanatorium, CABA, Argentina*

^b *Department of Dermatology, Holy Trinity Children's Hospital, Cordoba, Argentina*

^c *Department of Dermatology, Neonatal Maternal Hospital, 'Minister Dr. Ramon Carrillo', Cordoba, Argentina*

^d *Private practice, Buenos Aires, Argentina*

* Corresponding author.

E-mail: virlopezg.vl@gmail.com (V.R. Gamboa).

Received 31 August 2021; accepted 5 October 2021

Available online 20 July 2023

<https://doi.org/10.1016/j.abd.2021.10.019>

0365-0596/ © 2023 Sociedade Brasileira de Dermatologia.

Published by Elsevier España, S.L.U. This is an open access article under the CC BY license (<http://creativecommons.org/licenses/by/4.0/>).

Case for diagnosis. Multiple nodules on the scrotum[☆]



Dear Editor,

An 83-year-old male visited us complaining of multiple nodules on the scrotum that first appeared 20 years previously. They had been increasing in size and recently started to bleed easily. Physical examination revealed 2 exophytic and pedunculated red nodules sized 25 × 25 mm and 13 × 13 mm, which protruded from both sides of the scrotum (Fig. 1). He has a history of prostate cancer, obstructive hypertrophic cardiomyopathy, aortic regurgitation, chronic atrial fibrillation, chronic renal failure, and submucosal tumors of the esophagus. A biopsy specimen showed upwardly protruding tumors with acanthosis and papillomatosis (Fig. 2). The dermal papillae were covered by numerous foamy histiocytes and hyperplasia of capillaries (Fig. 3). The foamy cells were positive for Periodic Acid Schiff and CD68 antigen (Fig. 4).

What is your diagnosis?

- a) Viral wart;
- b) Condyloma acuminatum;
- c) Verruciform xanthoma;
- d) Adult xanthogranuloma.

Discussion

From the histopathological findings, the nodules were diagnosed as Verruciform Xanthoma (VX). Xanthogranuloma was excluded because Touton-type giant cells were not observed. Both of the nodules were surgically removed, and they showed the same histopathological fea-

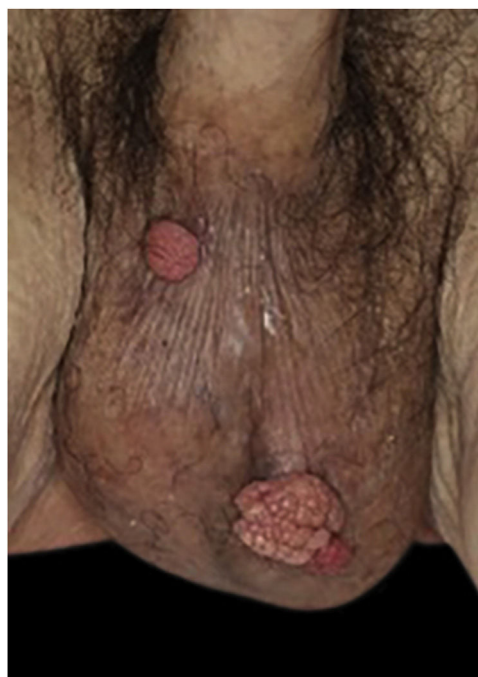


Figure 1 Well-circumscribed, exophytic and pedunculated nodules on the scrotum

[☆] Study conducted at the Department of Dermatology, Fukushima Medical University, Fukushima, Japan.