

Ming Yao <sup>1</sup>, Lang Rao <sup>\*,1</sup>*Department of Dermatology, Chengdu Second People's Hospital, Chengdu, Sichuan Province, China*

\* Corresponding author.

E-mail: 495593793@qq.com (L. Rao).

<sup>1</sup> These two authors contributed equally to this manuscript.Received 11 August 2021; accepted 30 September 2021  
Available online 29 June 2023<https://doi.org/10.1016/j.abd.2021.09.024>

0365-0596/ © 2023 Sociedade Brasileira de Dermatologia.

Published by Elsevier España, S.L.U. This is an open access article under the CC BY license (<http://creativecommons.org/licenses/by/4.0/>).

## Merkel cell carcinoma in a 38-year-old man: a case report<sup>☆</sup>



Dear Editor,

Merkel Cell Carcinoma (MCC) is a rare but aggressive cutaneous cancer, and it occurs mostly in older Caucasians, especially in immunocompromised patients. It is reported that up to 80% of MCC is associated with Merkel Cell Polyomavirus (MCPyV) infection, and 20% is related to ultraviolet.<sup>1</sup> The clinical presentation of MCC is nonspecific and varied, but most commonly presents with rapidly growing, solitary violaceous nodules with or without ulceration. Approximately 26%–36% of MCC patients have lymph node involvement and 6%–16% present with distant metastasis at their initial visit.<sup>2</sup> Surgery and radiotherapy are first-line treatments, while an emerging effective treatment modality is Immune Checkpoint Inhibitor (ICI).<sup>3</sup>

Herein, we report an extremely rare case of MCC in a young man with rapid deterioration to provide experience for the diagnosis and treatment.

### Case report

A 38-year-old man with a five-year history of unspecified lesion on the left index finger presented to our clinic for an asymptomatic nodule at the same site. In the beginning, he presented with an eczematous lesion on the left index finger in 2015 and just accepted ointment treatment. Then an erythematous nodule appeared and was removed by surgery in 2016 without pathological examination. A growing red-purple painless nodule measuring 52×51×39 mm appeared at the same site four years later, which seemed to be covered with small, widened vessels (Fig. 1). Moreover, physical examination showed dark red nodules with scaly scabs on his right thenar and right ankle. And he reported no trauma to these lesions and no systemic symptoms such as fever and weight loss. He was a dentist, lived in urban areas without an epidemic and denied family medical history and long-term administration of drugs. Moreover, HIV infection was ruled out.

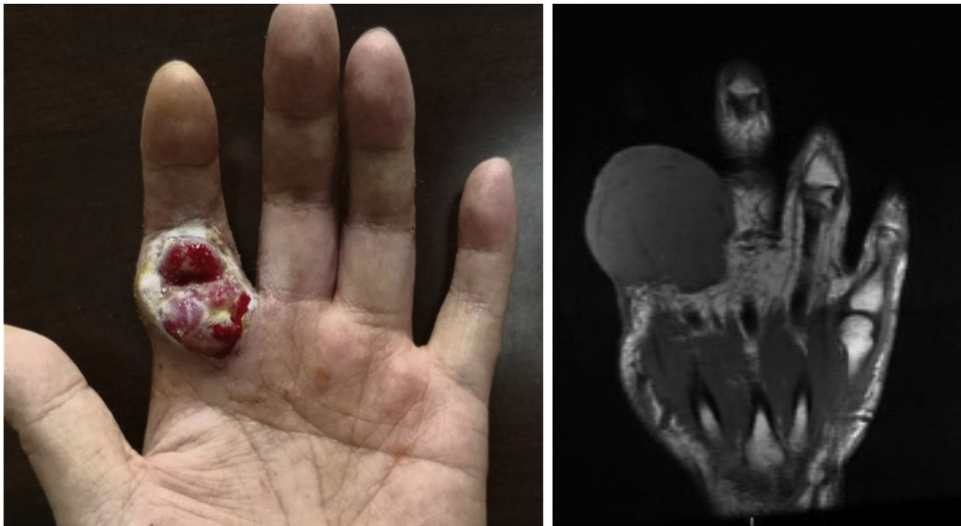
Wide excision of left index finger neoplasm and axillary lymph node dissection was performed in July 2020. The results of Hematoxylin-eosin staining and immunohistochemistry were in line with MCC histopathologic characteristics (Fig. 2). Besides, the pathological diagnosis for the other two lesions was Squamous Cell Carcinoma (SCC) and surgery was performed. The patient then accepted adjuvant therapy (Etoposide, Cisplatin, Pembrolizumab), routine blood tests, and renal and liver function were carefully monitored (Fig. 3). The disease maintained stable for four months. However, the liver was invaded by MCC in December 2020 (Fig. 4A), which suggested the adjuvant treatment was no longer effective. Given that he was still young, we offered a local radiotherapy (48Gy/16F) for hepatic metastases and tyrosine kinase inhibitor Apatinib was administered with the patient's consent. In February 2021, he presented with severe clinical worsening, and multiple enlarged cervical lymph nodes were observed (Fig. 4B). The patient eventually died 7 days after this admission.

The present report refers to an MCC patient under the age of 40 with poor therapeutic effect. Owing to its rarity, almost MCC treatment recommendations are derived from retrospective studies, and we take several potential factors that account for his poor immunotherapy response.

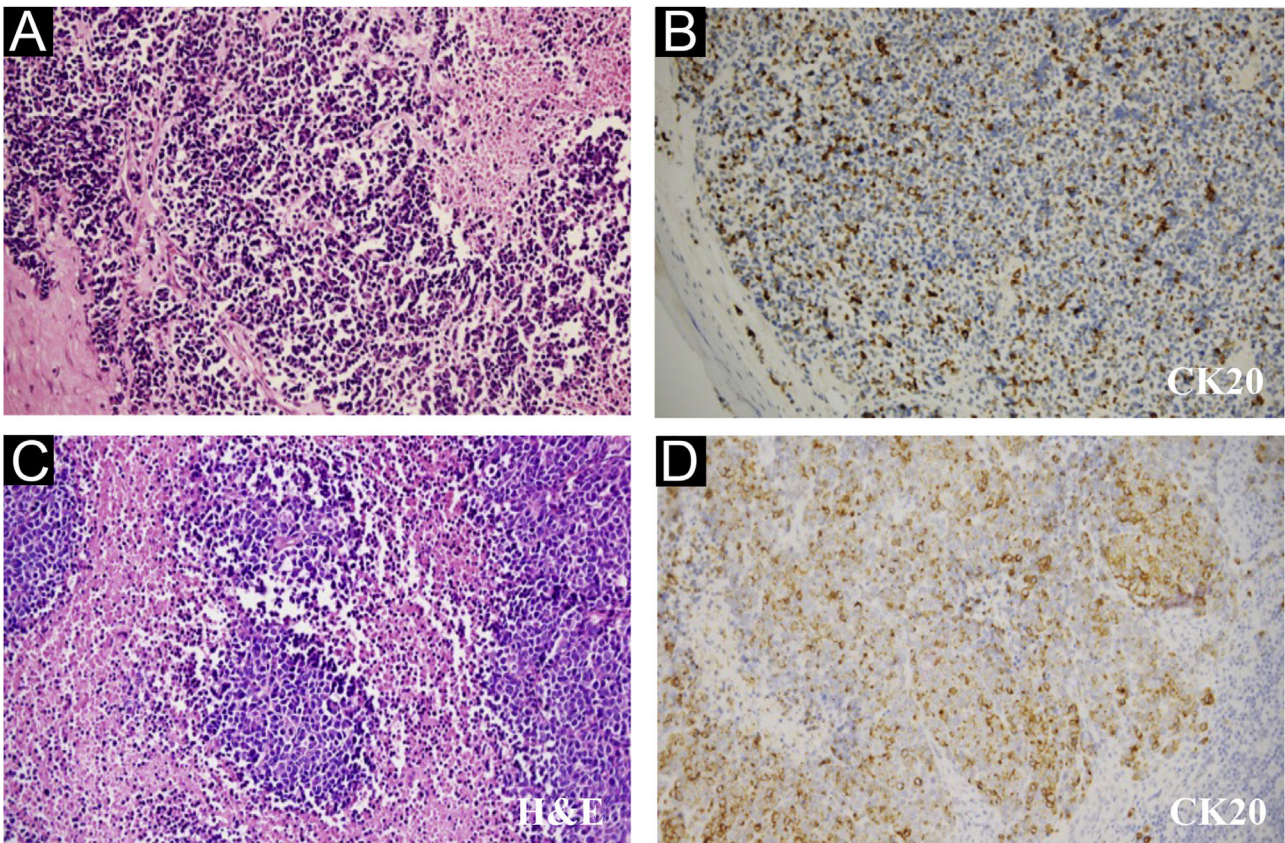
The first one to consider is age. Paulson<sup>4</sup> reported a higher fraction of metastases and a more aggressive course in younger MCC patients. MCC frequently was misdiagnosed due to non-specific clinical characterization and the patient mentioned above was treated as eczema for five years, which prevented him from timely treatment. Besides, there was a study indicating that neuroendocrine carcinomas associated with SCC had a higher incidence of local recurrence.<sup>5</sup> In our report, it is also noteworthy that the patient repeatedly appears lesions in the same skin site. But it is difficult to identify their connection because no pathological examination was carried out before this admission.

The Next Generation Sequencing results of peripheral blood showed no somatic variation within tumor genomes. What's more, this patient had a low tumor mutation burden (TMB) score (bTMB-L <1 Muts/Mb) as

<sup>☆</sup> Study conducted at the Department of Radiation and Medical Oncology, Zhongnan Hospital of Wuhan University, Wuhan, China.



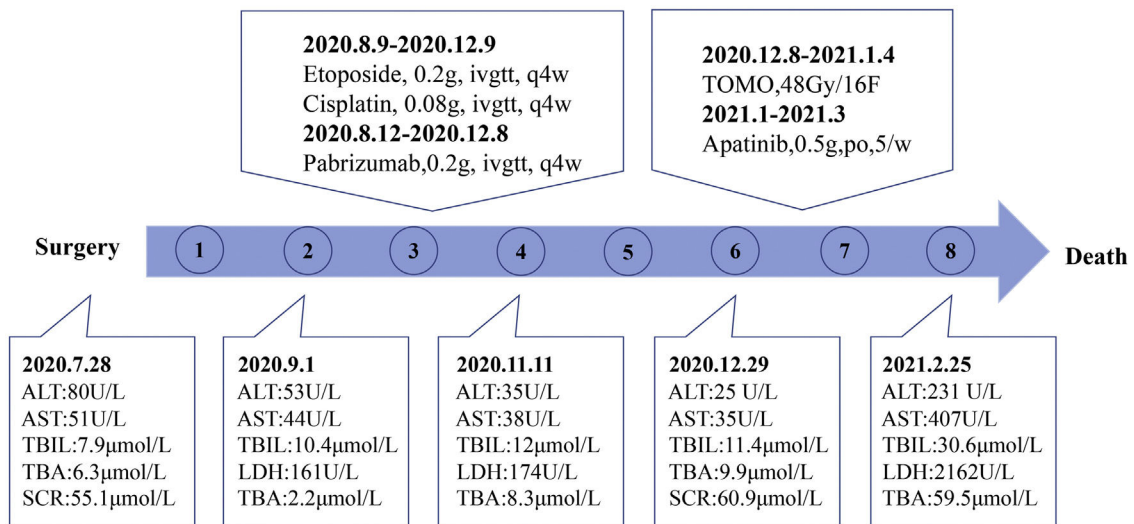
**Figure 1** Clinical images of skin lesion, July 2020. (A) Red-purple painless nodule in the left index finger. (B) A representative MRI image



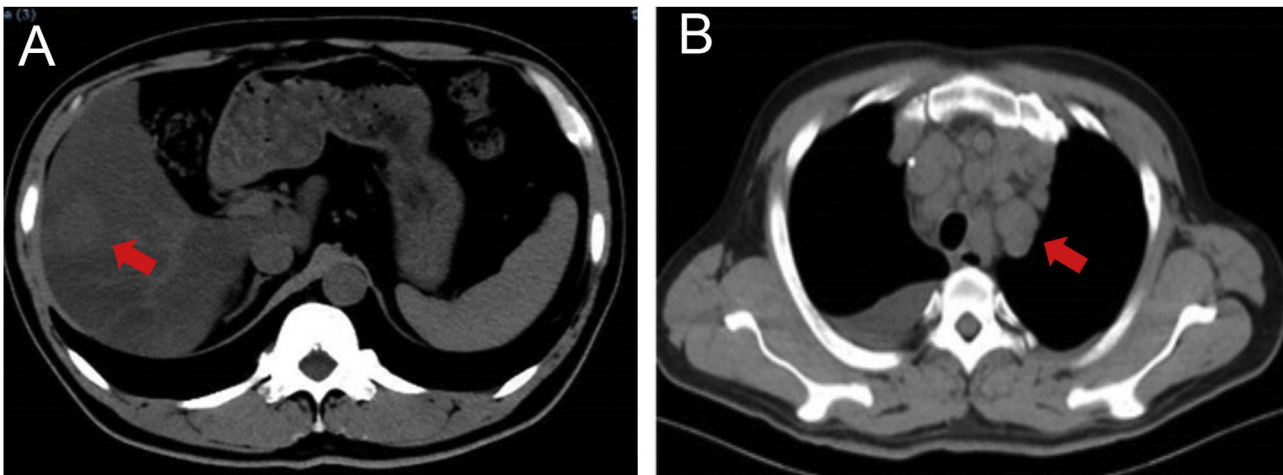
**Figure 2** Pathological features of the finger neoplasm (A-B) and left axilla lymph nodes (C-D). (CK20, Cytokeratin 20, 200 $\times$ )

well as relatively lower PD-L1 expression level (5%–10%) and CD8+ Tumor-Infiltrating Lymphocytes (TILs) density (10.01 psc/mm<sup>2</sup>), which are all immune-response related indicators in MCC.<sup>6</sup> In addition, MCC located in the extremities and involving the liver is also an important adverse feature.<sup>7,8</sup>

The patient in this case had higher malignancy and poorer therapeutic response owing to multiple factors. Therefore, we emphasize the importance of early biopsy, as well as adequate evaluation before treatment.



**Figure 3** Time Course. Blue dots indicated passing months after surgery



**Figure 4** Representative images of the patient. (A) Liver involvement, December 2020. (B) Multiple lymphadenectasis, February 2021

### Financial support

None declared.

### Authors' contributions

Yixin Liu: Data collection, writing of the manuscript.  
Wenjing Liang: Data collection, critical review of the manuscript.  
Qiongrong Chen: Critical review of the literature.  
Yongchang Wei: Approval of the final version of the manuscript.

### Conflicts of interest

None declared.

### References

1. Kaae J, Hansen AV, Biggar RJ, Boyd HA, Moore PS, Wohlfahrt J, et al. Merkel cell carcinoma: incidence, mortality, and risk of other cancers. *J Natl Cancer Inst.* 2010;102:793–801.
2. Bichakjian CK, Thomas O, Aasi SZ, Murad A, Andersen JS, Rachel B, et al. Merkel cell carcinoma, version 1.2018, NCCN clinical practice guidelines in oncology. *J Natl Compr Canc Netw.* 2018;16:742–74.
3. Nghiem PT, Bhatia S, Lipson EJ, Kudchadkar RR, Miller NJ, Annamalai L, et al. PD-1 blockade with pembrolizumab in advanced Merkel-cell carcinoma. *N Engl J Med.* 2016;374:2542–52.
4. Paulson KG, Nghiem P. One in a hundred million: Merkel cell carcinoma in pediatric and young adult patients is rare but more likely to present at advanced stages based on US registry data. *J Am Acad Dermatol.* 2019;80:1758–60.
5. Gomez LG, DiMaio S, Silva EG, Mackay B. Association between neuroendocrine (Merkel cell) carcinoma and squamous carcinoma of the skin. *Am J Surg Pathol.* 1983;7:171–7.

6. Zwijnenburg EM, Lubeek SFK, Werner JEM, Amir AL, Weijs WLJ, Takes RP, et al. Merkel cell carcinoma: new trends. *Cancers* (Basel). 2021;13:1614.
7. Lewis CW, Qazi J, Hippe DS, Lachance K, Thomas H, Cook MM, et al. Patterns of distant metastases in 215 Merkel cell carcinoma patients: Implications for prognosis and surveillance. *Cancer Med.* 2020;9:1374–82.
8. Xia YJ, Cao DS, Zhao J, Zhu BZ, Xie J. Frequency and prognosis of metastasis to liver, lung, bone and brain from Merkel cell carcinoma. *Future Oncol.* 2020;16:1101–13.

Yixin Liu <sup>a</sup>, Wenjing Liang <sup>a</sup>, Qiongrong Chen <sup>b</sup>, Yongchang Wei <sup>a,\*</sup>

<sup>a</sup> Department of Radiation and Medical Oncology, Zhongnan Hospital of Wuhan University, Wuhan, China

<sup>b</sup> Department of Pathology, Zhongnan Hospital of Wuhan University, Wuhan, China

\* Corresponding author.

E-mail: [weiyongchang@whu.edu.cn](mailto:weiyongchang@whu.edu.cn) (Y. Wei).

Received 15 February 2022; accepted 11 May 2022

Available online 29 June 2023

<https://doi.org/10.1016/j.abd.2022.05.009>

0365-0596/ © 2023 Published by Elsevier España, S.L.U. on behalf of Sociedade Brasileira de Dermatologia. This is an open access article under the CC BY license (<http://creativecommons.org/licenses/by/4.0/>).

## Ophthalmological complications related to the use of microfocused ultrasound in the periocular region and face<sup>☆</sup>



Dear Editor,

The authors describe a severe clinical case of ophthalmologic complications related to the use of microfocused ultrasound (MU) in the periocular region and face. It is extremely important to know about this possible complication of the use of MU.

A 50-year-old female patient sought dermatological care for facial rejuvenation. After evaluation, MU was employed on the face and periocular region, with carboxytherapy being performed on the eyelids. There were no complications during the procedures, which were followed by the application of Cicaplast<sup>®</sup> cream on the palpebral region. Immediately after the procedure, she complained of visual blurring, initially attributed to the use of Cicaplast<sup>®</sup>. On the first and second days after the procedure, she developed edema and erythema limited to the orbicularis region, while the visual blurring persisted and she started to have scotomas, lacrimation, and, finally, eye pain. On the third day, she experienced worsening of the ophthalmological condition, making it impossible to perform her daily activities, due to visual blurring and pain.

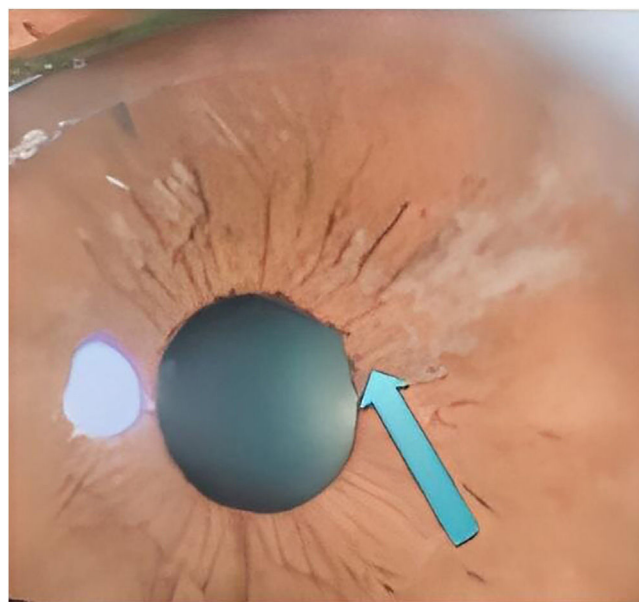
She was assessed by an ophthalmologist who found a significant increase in eye pressure, iris retraction, areas of fibrosis (Fig. 1), and crystalline lens atrophy in the shape of spicules, and she was diagnosed with acute angle-closure glaucoma and cataracts in the shape of spicules.

Treatment was implemented with maximum doses of timolol, brimonidine, bimatoprost, and acetazolamide eye drops; however, there was some difficulty in reducing ocular pressure and little improvement of symptoms. Surgical intervention was then considered to preserve the optic

nerve. After six months of treatment, she showed partial remission of symptoms, but still uses eye drops every other day.

MU is used for the treatment of body flaccidity, contouring, and muscle anchoring.<sup>1</sup> It acts by emitting vibrating waves, which generate molecular friction and heat, creating an area of coagulation. This leads to a tissue healing and retraction process (lifting).<sup>1,2</sup> According to the vibratory frequency, its energy is concentrated on a certain layer of the superficial musculo-aponeurotic system and promotes the aforementioned process.<sup>1,3</sup> Because of that, it is important to pay attention to the correct use of the technique, which consists in using the appropriate tip, respecting the pre-established number of discharges for each area and, above all, never pointing the transducer towards the eyes, when it is used on the periocular or facial regions.<sup>2,3</sup>

Similar cases have been previously observed, in which state-of-the-art devices were used and coursed with equiv-



**Figure 1** Patient's ophthalmoscopy, showing iris retraction and areas of fibrosis

<sup>☆</sup> Study conducted at the Instituto de Dermatologia Professor Rubem David Azuly, Santa Casa da Misericórdia do Rio de Janeiro, Rio de Janeiro, RJ, Brazil.